

Student's Corner

Become a Sherlock Holmes in ECG

M Chenniappan¹

Series 8 :

“Premature Predictions”

Routine ECG of 50 years old patient with known CAD.

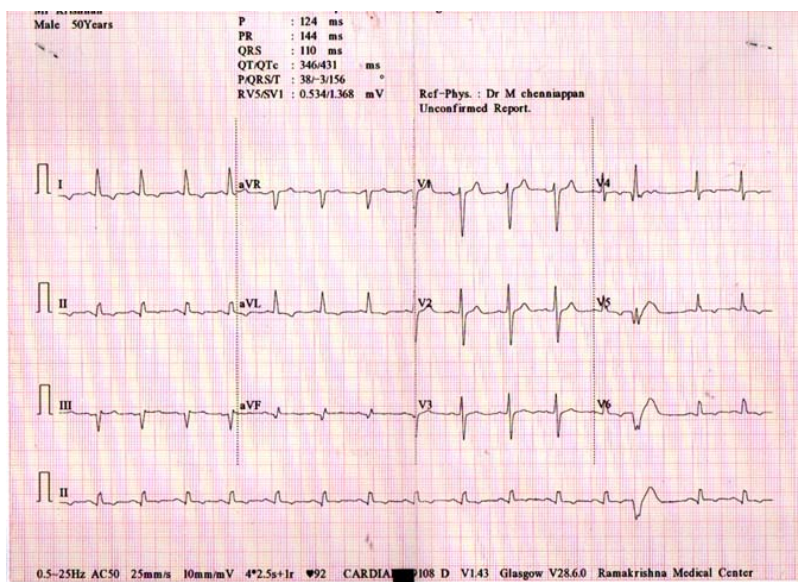
Questions :

- (1) Describe all ECG changes
- (2) Why is this clue?
- (3) What are practical implications?

Answers :

ECG CHANGES :

ECG shows normal sinus rhythm with chronic stabilized phase of inferior wall myocardial infarction (IWMI). There are anterolateral and high lateral minor T wave inversions. The inferior wall infarction is likely to be due to right coronary occlusion because of the deepest Q is seen in LIII. In addition, there is a ventricular premature depolarization (VPD) in V4, V5, V6 and rhythm strip of LII. This VPD shows negative QRS complex in V6 suggestive of LV origin and negative QRS in LII is suggestive of inferior origin. So this VPD is likely to come from left posterior fascicular distribution area which is infarcted. In addition, VPDs in V4, V5 show pathological Q wave with small qR complex in V4, QRS complex in V5. This pattern is suggestive of chronic MI or scar in this region, although the basic sinus beats are not showing the infarct pattern. Infarction was diagnosed from the morphology of a VPD when it has a QR or QRS pattern with Q wave greater than or equal to 0.04 second. Morphologic analysis of VPDs had a low sensitivity but high specificity and high predictive value for the diagnosis of MI. In some ECGs, angiographic MI had no MI according to standard electrocardiographic criteria, but did have an MI manifested by VPB morphologic analysis. Despite low sensitivity, analysis



of the morphology of VPBs may be useful for the diagnosis of MI when the morphology of sinus beats is not diagnostic. Therefore, VPD analysis is complementary to the standard electrocardiographic diagnosis of MI.

CLUE :

The ventricular premature beats are predicting following features

1. The site of origin; left posterior fascicular area
2. VPDs are arising from infarct area itself
3. VPDs are unmasking the chronic MI or scar in low septal and anterolateral areas even though the sinus beats are not showing the infarct pattern.

Because of these predictions by ventricular premature beats the clue of “Premature Predictions” is given.

PRACTICAL IMPLICATIONS :

In addition to IWMI, the VPD has unmasked additional MI in low septal and lateral areas which may need detailed investigations such as ECHO for LV function, Holter to decide about the malignancy of VPDs and coronary angiography to decide about revascularisation. The further management of CAD and this VPD depends upon the results of these investigations.

¹Adjunct Professor, Dr MGR Medical University, Tamilnadu; Senior consultant cardiologist, Tamilnadu; Ramakrishna Medical Centre, Apollo Speciality Hospital, Trichy