

Review Article

Diagnostic Laparoscopy — A Useful Diagnostic Tool

Sandeep Verma¹, Navneet Kumar Chaudhry²

Diagnostic Laparoscopy (DL) is a minimal invasive surgical procedure for diagnosis of intraabdominal diseases through direct inspection of various intra-abdominal organs and peritoneal cavity. Owing to the lower recovery time, less post-procedural pain, decreased hospital stay and fewer complications compared to open surgery, it is a safer and effective option for both patient and the surgeon. It has been proven to be an extremely useful tool in the management of surgical emergencies. The advent of DL represents a landmark in surgery that initiated a shift from an era of open abdominal surgery to minimally invasive surgery. The aim of this review is a critical examination of available literature on the role of diagnostic laparoscopy.

[*J Indian Med Assoc* 2021; **119**(12): 62-62]

Key words : Diagnostic laparoscopy, MIS, NSAP, Abdominal trauma, Malignancy.

The word laparoscopy is derived from the Greek laparo, meaning “flank,” and scope, meaning “an instrument for observation.” Laparoscopy is examining the peritoneal cavity. It was first attempted in 1901 by George Kelling who called this examining procedure “Celioscopy”. The experiments were performed on live dogs. He insufflated the canine’s abdomen with oxygen filtered through sterile cotton and utilizing a cystoscope to inspect the abdominal contents¹. Laparoscopy was developed in the beginning of 20th century, and it was promoted as a valuable adjunct to the diagnosis of abdominal diseases.

The origin and development of minimal access surgery are rooted in men’s insatiable curiosity. The recent meteoric rise of elective laparoscopic surgical procedures has ignited the interest in the possible role of laparoscope in the evaluation of various abdominal conditions. Diagnostic laparoscopic (DL) also termed as explorative laparoscopy, is a minimally invasive surgery (MIS) for the diagnosis of intraabdominal diseases.

DL facilitates direct inspection of intraabdominal organs, the acquisition of biopsy specimens, cultures and aspirates, allows the use of laparoscopic ultrasound and makes therapeutic interventions possible. DL is a safe, well tolerated procedure that can be performed in an inpatient or outpatient setting under general anesthesia (GA) or occasionally local anesthesia (LA) with intravenous sedation in carefully selected patients. DL has been proposed as a diagnostic tool in the management of suspected intraabdominal trauma².

The goal of this review article is to provide assessment of the value of DL in intraabdominal diseases and injuries. The indications,

Editor's Comment :

- Diagnostic Laparoscopy has proven to be a useful tool in the management of various abdominal pathologies, both in elective and emergency surgical conditions.
- It allows for safer and effective management of various intraabdominal surgical conditions, with fewer complications as compared with conventional open surgery.
- The ongoing advancements in the instrumentation and training of surgeons provides a wider scope for Diagnostic Laparoscopy.

contraindications, risks, benefits, diagnostic accuracy of procedure and associated morbidity are discussed.

Indications :

Trauma :

Diagnostic laparoscopy is uniquely useful in the evaluation of hemodynamically stable patients who have sustained blunt or penetrating trauma. It can provide accurate diagnosis of intra-abdominal injuries, thereby reducing non-therapeutic laparotomies and associated complications. In trauma settings, DL has safely been used as a diagnostic tool where the mechanism of injury and clinical presentation needs closer inspection. Yet after years of experience surgeons are reluctant to use laparoscopy in trauma for definitive treatment³.

Indications of DL in hemodynamically stable trauma patients include:

- Suspected intra-abdominal injury despite a negative initial workup after blunt trauma.
- Abdominal stab wounds with proven or equivocal penetration of fascia where abdominal organ injury is suspected.
- Diagnosis of diaphragmatic injury from penetrating trauma to thoracoabdominal area.
- Abdominal gun shots wound with doubtful intraperitoneal trajectory.
- Creation of a transdiaphragmatic pericardial window to rule out cardiac injury.

¹MBBS, Senior Resident

²MBBS, Postgraduate Trainee, Department of Surgery, SPS Hospital, Ludhiana 141003

Received on : 03/06/2021

Accepted on : 20/07/2021

In United Kingdom (UK), National Institute for Health and Care Excellence (NICE) guidelines for major trauma are under consideration but each major trauma centre developed their own protocol based on local resources and experience⁴.

Laparoscopy reduces the incidence of non-therapeutic laparotomy. Patients undergoing DL require fewer opioids doses as compared to patients undergoing laparotomy⁵. Laparoscopy has specificity and sensitivity rates of 100% and 92% respectively, in detecting injuries⁶.

Direct visualization using laparoscopy is more accurate than Computed Tomography (CT) and Ultrasonography (USG) in detecting solid organ injuries and diaphragmatic tears or ruptures⁷.

According to European Association for Endoscopic Surgery (EAES), consensus statement on laparoscopy for abdominal emergencies 2012 by Italian Society of Endoscopic Surgery (SICE):

- After penetrating trauma of the abdomen, laparoscopy may be useful in hemodynamically stable patients with documented or equivocal penetration of anterior fascia [Grade of Recommendation (GOR) -B].

- Laparoscopy should be considered in hemodynamically stable blunt trauma patients with suspected intra-abdominal injury and equivocal findings on imaging studies or even in patients with negative studies but with a high clinical likelihood for intraabdominal injury (unclear abdomen) to exclude relevant injury (GOR-C)

- To optimize results, the procedure should be incorporated in institutional diagnostic and treatment algorithms for trauma patients (GOR-D)⁸ (Fig 1).

The universal application of DL in trauma patients is limited by prolonged operating room (OR) time to set up equipment, which may delay therapeutic intervention and the difficulty to identify certain injuries, such as bowel injuries and retroperitoneal injuries.

Acute abdominal pain :

NSAP is defined as acute abdominal pain which extends for duration of less than seven days where the diagnosis remains uncertain after baseline examination and diagnostic tests. The most common causes for acute abdominal pain includes the nonspecific abdominal pain (NSAP) followed by acute appendicitis, acute biliary disease, bowel obstruction and diverticulitis⁹.

DL is helpful in the diagnosis of nonspecific abdominal pain (NSAP). NSAP has been treated either with open exploratory laparotomy for presumed conditions or with active observation. But these approaches are associated with prolonged hospital stays, negative laparotomies, higher numbers of radiologic imaging studies and patient dissatisfaction if

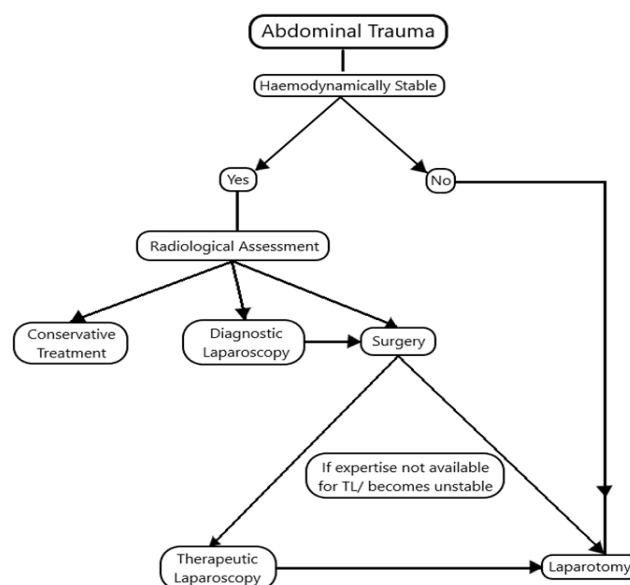


Fig 1 — Flowchart of management of abdominal trauma⁹

the diagnosis cannot be established. This scenario is more prevalent in pregnant women and obese patients, in whom availability of or access to imaging studies is limited by the gestational age or the patient's size¹⁰.

DL has several advantages as it allows the visualization of the entire abdominal cavity, localization of intra-abdominal pathology, can take peritoneal fluid for cultures or cytology and ability to irrigate the peritoneal cavity to decrease contamination. In most of cases where causes are identified, therapeutic intervention make it more useful tool¹¹.

Many studies have demonstrated the feasibility, high diagnostic accuracy and safety of DL using GA for patient with acute abdomen pain^{12, 13}.

In a randomized trial for acute NSAP documented that early DL significantly improve diagnostic accuracy in comparison to an observation group (81% versus 36%)¹².

In a prospective study of 100 patients concluded that the best approach in abdominal pain is to do DL rather than going for open laparotomy¹³.

DL is recommended in NSAP as it is technically feasible and can be applied safely for selected patients with acute NSAP after a complete diagnostic work-up (GOR-A)^{8,10}.

DL should be avoided in patients with hemodynamic instability and may have a limited role in patients with severe abdominal distension or a clear indication for laparotomy (GOR- C).

DL should be considered in patients without a specific diagnosis after appropriate clinical examination and imaging studies (GOR- C)¹⁰.

Malignancy :

Frequently on exploration, it is found that the disease is inoperable because of metastasis or locally advanced

disease, despite negative preoperative workup which suggested primarily resectable disease¹⁴.

DL for accurate staging of intra-abdominal malignancies is known as staging laparoscopy and is a standard part of the staging workup for a number of cancer subtypes. Staging laparoscopy is useful in evaluation of intraabdominal malignancies—

- To identify resectability of primary tumour like oesophagus, stomach, pancreas, cholangiocarcinoma.
- To stage the malignancy, prior to administration of neoadjuvant chemotherapy or radiation therapy.
- To assess the equivocal magnetic resonance imaging (MRI), contrast enhanced computer tomography (CECT) scan, positron emission tomography (PET) scan findings for primary, regional, or distant disease.
- To assess the inconclusive histology following radiographic-guided fine needle aspirations (FNA) of suspicious sites of disease.
- To assess for resectability of liver metastasis in patients with colon or rectal cancer.

DL is cost effective if malignancy is found to be unresectable and patient is spared from laparotomy but overall DL increases the cost of whole procedure¹⁵.

Many studies showed that DL has an accuracy of 89-100% for staging, avoids non-therapeutic laparotomy in 13-57% of gastric patients despite a negative preoperative imaging workup and identifies occult metastasis or unresectable disease¹⁴.

DL in gastric malignancies, it was found that DL had accuracy, sensitivity, specificity in finding metastasis ranging from 85% - 98.9%, 64.3 - 94% and 80 - 100% respectively. Thus, DL has substantial value in staging patients with gastric cancer and helps to avoid unnecessary laparotomy¹⁶.

DL should be considered in localised or locally advanced T3 or T4 tumour patients despite a high-quality preoperative imaging. Unsuspected metastatic disease is found in 13% to 57% of patients. For detecting hepatic metastasis DL is more sensitive (96%) than CT (52%) or USG (37%). DL can be safely performed for patients with oesophageal cancer, pancreatic cancer, hepatocellular carcinoma, biliary tract tumour and colorectal cancers and can alter the staging of disease and management. Diagnostic accuracy is higher in larger tumors, tumors of pancreatic body, neck and tail, high level of CA 19.9¹⁰.

Intensive Care Unit (ICU) :

DL has excellent accuracy in diagnosing common causes of ICU related conditions like intra-abdominal abscess, ischemic bowel, calculus or gangrenous cholecystitis and perforated viscus.

Transporting critically ill patients to and from the radiology department for diagnostic testing is associated

with significant risk of adverse events. Bedside DL performed for critically ill patients who are unstable, require mechanical ventilator or inotropic support is performed within ICU with local anaesthesia or IV sedation to enable therapeutic intervention, facilitate the diagnosis and avoid morbidity of laparotomy¹⁷.

DL is indicated in patients in ICU with following conditions like unexplained sepsis, SIRS, multiorgan failure, unexplained metabolic acidosis, abdominal pain with signs of sepsis and without obvious indication for laparotomy and increased abdominal distension that is not a consequence of bowel obstruction¹⁸.

Despite numerous indications adoption of MIS to ICU patients remains in relatively in few case series. DL has succeeded in decreasing in the number of non-therapeutic laparotomies.

Bedside DL in ICU patient is safe, feasible, accurately diagnose the intraabdominal pathologies in properly selected, critically ill patients. The procedure appears to be have excellent accuracy in diagnosing acalculous cholecystitis, ischemia and avoid the unnecessary laparotomy. However, DL is still underutilised in ICU setups.

Pyrexia of Unknown Origin (PUO) :

Pyrexia of Unknown Origin (PUO) is defined as fever of 38.3°C (101°F) or higher for more than 3 weeks under study without an established diagnosis.

Despite advancement in various investigating tools, the origin of the fever remains undetermined in 7% to 20% of patients. Several studies showed that number of patient require laparotomies for the diagnosis¹⁹.

DL is found to be most useful (76.6 %) in those patients with physical signs or biochemical results suggestive of an abdominal disorder. In absence of clinical sign and symptoms of abdominal disease, it is very difficult to decide which patient should undergo exploration²⁰.

Consistent advancement in Laparoscopic technique have led to a protocolized exploration by laparoscopy which includes wedge and tru-cut biopsy of liver, retroperitoneal lymph node biopsy and splenectomy²¹. DL is found to have an overall sensitivity of 90.9% and a specificity of 100% and is a useful last-step procedure in the diagnostic work-up for patients with POU²².

Abdominal tuberculosis (TB) is the sixth most common form of extra-pulmonary site of infection after lymphatic, genitourinary, bone and joint, miliary and meningeal TB. It remains a diagnostic challenge as it mimics different abdominal diseases causing delayed diagnosis. A high degree of suspicion is needed for diagnosis of this condition. Moreover, radiological investigations (USG and CECT) have nonspecific findings. CT scan can miss small granuloma in miliary

TB of liver and require biopsy for the diagnosis.

Therapeutic trial with antitubercular treatment is not warranted. Thus, histological evidence holds a great importance. DL is helpful for the diagnosis of abdominal TB, especially in the presence of peritoneal involvement. Differentiation between Crohn's disease and abdomen TB is very difficult and DL is a useful procedure in this situation²³.

Technique Consideration :

Patient education and consent :

Patient should be counselled regarding the inherent risks associated with laparoscopic procedure such as conversion to open surgery due to failure to progress, intestinal injury, haemorrhage, fat gas embolism, pneumothorax, hypercarbia.

Equipment :

The basic equipment necessary to perform DL include laparoscope, video camera, light source, display monitor, insufflation system (insufflator tubing, chosen gas for pneumoperitoneum, Veress needle), instrument for grasping and dissection, incising and haemostasis, clipping and stapling, biopsy and specimen retrieval, suction, irrigation and retractors.

Patient preparation :

Povidone iodine solution is used for scrubbing and draping from nipple to mid-thigh. A prophylactic antibiotic first or second-generation cephalosporin is to be given. DL is most commonly performed under general anaesthesia and skeletal muscle relaxant. Positioning of majority of the abdominal DL is performed in supine position whereas for pelvic pathologies lithotomy position is favoured.

Technique :

Before making skin incision, light source, carbon dioxide tank, irrigation aspiration unit, electro cautery unit, insufflation system is checked. According to the suspected pathology the access port, camera port, any additional trocars are placed either supraumbilically or infraumbilically. Detailed examination of the peritoneal cavity is performed after placement of port.

In acute pain abdomen, depending on suspected site of pathology (appendicitis, cholecystitis, and diverticulitis) grossly examine for erythema, fibrinous exudates, inflammatory adhesions, or formation of phlegmon. Nontraumatic intestinal graspers are used to deal with the intestine and omentum. Fluid in the peritoneal cavity or pelvis should be aspirated and send for relevant tests²⁴.

In patients with intra-abdominal malignancy, a systematic examination of the primary tumour site, all abdominal viscera and the pelvis is performed to identify evidence of metastasis. The primary tumour is assessed to detect direct extension into contiguous organs. If there is evidence of widespread or peritoneal-

based disease or liver metastasis or if there is a direct extension of the primary tumour to surrounding structures that renders the tumour unresectable, diagnostic laparoscopy is terminated after confirmatory biopsy specimens are taken²⁵.

In case of trauma patients who are hemodynamically stable, DL is started with examining diaphragm, liver, gall bladder, spleen, anterior wall of stomach, gastro colic ligament, posterior wall of stomach, pancreas, duodenum above and below of mesocolon, whole remaining small bowel from ligament of Treitz to ileocaecal junction, colon and pelvic organs. Suctioning of blood clots, gastrointestinal contents and bleeding should be controlled with nontraumatic grasper followed by laparoscopic vascular clamp, clips, energy sources or ligation. If bleeding is uncontrollable laparoscopically, convert to laparotomy to manage bleeding. Examination of intraperitoneal and retroperitoneal region is done systematically, which is guided by preoperative imaging or clinical findings. If retroperitoneal penetration is present then may require inferior vena cava and aorta exploration, otherwise usually not required²⁶.

Port closure :

Meticulous examination is done to ensure haemostasis. Any port site 10mm or above must be closed. Finally, skin can be closed with nylon or subcuticular sutures.

Contraindications of DL:

Patient selection for DL with identification of relative or absolute contraindications is vital to a successful outcome from a laparoscopic procedure.

Absolute contraindications of DL include patients who cannot tolerate pneumoperitoneum, any obvious indication for laparotomy like peritonitis, bowel obstruction causing massive dilatation, coagulopathy and abdominal compartment syndrome. In trauma patients, hemodynamic instability or clear indication of bowel injuries such as presence of bile or evisceration are contraindications of DL.

Morbid obesity, cardiopulmonary compromise, pregnancy, aortoiliac aneurysmal diseases, ICU patients who cannot tolerate pneumoperitoneum, anterior abdominal wall cellulitis are relative contraindications²⁷.

Complications :

Complications of DL includes —

- Anaesthesia related complications include same risk of complications seen with general anaesthesia in any open procedure but specifically in DL reduced oxygenation and hypercarbia due to raised intraabdominal pressure.
- Access related complications include bowel injury, solid organs injury, omental injury, bladder injury,

extra peritoneal insufflation and vascular injuries.

- Insufflation related complications include air embolism, hemodynamic instability, pneumothorax, subcutaneous emphysema.
- Inadequate visualisation leads to delay in diagnosis, missed injuries, delay in definitive treatment.
- Postoperative complications include port site hernia, bleeding, hernia and port site recurrence⁽²⁸⁾.

CONCLUSION

Laparoscopic surgery is a viable, safe, effective and beneficial option to both patient and the surgeon. It has improved the management of surgical emergencies and is now an essential part of surgeon's armamentarium in certain conditions. With advancements in instrumentations, anesthesia and better training of surgeons, the role for DL will expand.

REFERENCES

- Spaner SJ, Warnock GL — A brief history of endoscopy, laparoscopy, and laparoscopic surgery. *J Laparoendosc Adv Surg Tech A* 1997; **7(6)**: 369-73. doi: 10.1089/lap.1997.7.369. PMID: 9449087.
- Stefanidis D, Richardson WS, Chang L — The role of diagnostic laparoscopy for acute abdominal conditions: an evidence-based review. *Surg Endosc* 2009; **23**: 16. <https://doi.org/10.1007/s00464-008-0103-x>
- Bain K, Meytes V, Chang GC, Timoney MF — Laparoscopy in penetrating abdominal trauma is a safe and effective alternative to laparotomy. *Surg Endosc* 2019; **33(5)**: 1618-25. doi: 10.1007/s00464-018-6436-1. Epub 2018 Sep 12. PMID: 30209608.
- Chakravarty S, Sarma DR, Noor M, Panagiotopoulos S, Patel AG — Laparoscopy has a therapeutic role in the management of abdominal trauma: A matched-pair analysis. *Int J Surg* 2017; **44**: 21-5. doi: 10.1016/j.ijssu.2017.05.035. Epub 2017 May 18. PMID: 28529193.
- Khubutiya M, Yartsev PA, Guliaev AA — Laparoscopy in blunt and penetrating abdominal trauma. *Surg Laparosc Endosc percutaneous Tech* 2013; **23**: 507e512.
- Kaban GK, Novitsky YW, Perugini RA, Haveran L, Czerniach D, Kelly JJ, et al — Use of laparoscopy in evaluation and treatment of penetrating and blunt abdominal injuries. *Surg Innov* 2008;
- Ivatury RR, Simon RJ, Stahl WM — Selective celiotomy for missile wounds of the abdomen based on laparoscopy. *Surg Endosc* 1994; **8**: 366-9. doi: 10.1007/BF00642432.
- Agresta F, Ansaloni L, Baiocchi GL, Bergamini C, Campanile FC, Carlucci M, et al — Laparoscopic approach to acute abdomen from the Consensus Development Conference of the Società Italiana di Chirurgia Endoscopica e nuove tecnologie (SICE), Associazione Chirurgi Ospedali Italiani (ACOI), Società Italiana di Chirurgia (SIC), Società Italiana di Chirurgia d'Urgenza e del Trauma (SICUT), Società Italiana di Chirurgia nell'Ospedalità Privata (SICOP), and the European Association for Endoscopic Surgery (EAES). *Surg Endosc* 2012; **26(8)**: 2134-64. doi: 10.1007/s00464-012-2331-3. Epub 2012 Jun 27. PMID: 22736283
- SAGES. 2010 — Guidelines for Diagnostic Laparoscopy - A SAGES Publication. [online] Available at: <<https://www.sages.org/publications/guidelines/guidelines-for-diagnostic-laparoscopy/>> [Accessed 2 May 2021].
- Pearl JP, Price RR, Tonkin AE, Richardson WS, Stefanidis D — SAGES guidelines for the use of laparoscopy during pregnancy. *Surg Endosc* 2017; **31(10)**: 3767-82. doi: 10.1007/s00464-017-5637-3. Epub 2017 Jun 22. PMID: 28643072.
- Schieltroma M, Cappelli S, Carlei F, Pescosolido A, Lygidakis NJ, Amicucci G — Acute abdomen": early laparoscopy or active laparotomic-laparoscopic observation? *Hepatogastroenterology* 2007; **54(76)**: 1137-41. PMID: 17629056.
- Decadt B, Sussman L, Lewis MP, Secker A, Cohen L, Rogers C, et al — Randomized clinical trial of early laparoscopy in the management of acute nonspecific abdominal pain. *Br J Surg* 1999; **86**: 1383-138.
- Subramaniam R — Diagnostic laparoscopy in acute abdominal pain. *International Surgery Journal* [Online] 2019; **6(4)**: (26th March 2019)
- Mayo SC, Austin DF, Sheppard BC, Mori M, Shipley DK, Billingsley KG — Evolving preoperative evaluation of patients with pancreatic cancer: does laparoscopy have a role in the current era? *J Am Coll Surg* 2009; **208(1)**: 87-95. doi: 10.1016/j.jamcollsurg.2008.10.014. PMID: 19228509.
- Yeola ME, Gode D, Bora AK — Diagnostic Laparoscopy as an Effective Tool in Evaluation of Intraabdominal Malignancies. *World J Lap Surg* 2018; **11(2)**: 68-75.
- Leake PA, Cardoso R, Seevaratnam R, Lourenco L, Helyer L, Mahar A, et al — A systematic review of the accuracy and indications for diagnostic laparoscopy prior to curative-intent resection of gastric cancer. *Gastric Cancer*. 2012 Sep; **15** Suppl 1:S38-47. doi: 10.1007/s10120-011-0047-z. Epub 2011 Jun 11. PMID: 21667136.
- Peris A, Matano S, Manca G, Zagli G, Bonizzoli M, Cianchi G, et al — Bedside diagnostic laparoscopy to diagnose intraabdominal pathology in the intensive care unit. *Crit Care* 2009; **13(1)**: R25. doi: 10.1186/cc7730. Epub 2009 Feb 25. PMID: 19243621; PMCID: PMC2688143.
- Zemlyak A, Heniford BT, Sing RF — Diagnostic Laparoscopy in the Intensive Care Unit. *Journal of Intensive Care Medicine* 2015; **30(5)**: 297-302. doi:10.1177/0885066613492102
- Mori M, Bohle U — The indications for laparoscopy in internal medicine. *Dtsch Med Wochenschr* 1993; **45**: 1649-51
- Solis-Herruzo JA, Benita V, Morillas JD — Laparoscopy in fever of unknown origin - study of seventy cases. *Endoscopy* 1981; **13(5)**: 207-10. doi: 10.1055/s-2007-1021685. PMID: 6456143.
- Herrera MF, Lozano-Salazar RR, Bezaury P, Ce'sarman G, Herma'ndez G, Sa'nchez SA, et al — Esplenectomia laparoscópica en pacientes con pu'rpuratrombo-citopení'ca autoinmune. *Rev Invest Clin* 1998; **50**: 127-32.
- Arch-Ferrer JE, Velázquez-Fernández D, Sierra-Madero J, López-Karpovitch X, Angeles-Angeles A, Gamino R, et al — Laparoscopic approach to fever of unknown origin. *Surg Endosc* 2003; **17(3)**: 494-7. doi: 10.1007/s00464-002-8589-0. Epub 2002 Nov 20. PMID: 12436232.
- Safarpor F, Aghajanzade M, Kohsari MR, Hoda S, Sarshad A, Safarpor D — Role of laparoscopy in the diagnosis of abdominal tuberculosis. *Saudi J Gastroenterol* 2007; **13**: 133-5
- Morsy MM, Mostafa TA, Hassan MM — Role of laparoscopy in acute abdomen. *Egypt J Surg* 2020; **39**: 540-6.
- Nair C, Kothari K — Role of diagnostic laparoscopy in assessing operability in borderline resectable gastrointestinal cancers. *Journal of Minimal Access Surgery* 2012; **8(2)**: 45. doi:10.4103/0972-9941.95533
- Koto MZ, Matsevych OY, Aldous C — Diagnostic Laparoscopy for Trauma: How Not to Miss Injuries. *J Laparoendosc Adv Surg Tech A* 2018; **28(5)**: 506-513. doi: 10.1089/lap.2017.0562. Epub 2018 Jan 2. PMID: 29293406.
- Buote NJ, Mcclaran JK — Laparoscopic Contraindications, Complications, and Conversion. *Small Animal Laparoscopy and Thoracoscopy* 2015; 93-102. doi:10.1002/9781118845912.ch10
- Kindel T, Latchana N, Swaroop M — Laparoscopy in trauma: An overview of complications and related topics. *Int J Crit Illn Inj Sci* 2015; **5(3)**: 196-205. doi:10.4103/2229-5151.165004.