

Case Report

Schwannoma of the cervical vagus nerve mimicking glomus tumor on MRI : a case report

Gurukiran CS¹, Pavan BM², Kiran Kumar KM³, Manjunath SK⁴, Fahad Tauheed⁵

Nerve sheath tumors arising from the cervical vagus nerve are extremely rare, and are of diagnostic challenge. We report A 14-year old male presented with swelling in the left side of neck for the past 6 months. FNAC revealed a vascular lesion, MRI scan showed a well circumscribed mass, 4 × 4 cm located in the lateral part of neck and was suggestive of a Glomus tumor. At surgery the swelling was found to be in close proximity with the internal jugular vein and common carotid artery and the vagus nerve on the left side. The encapsulated tumor was completely resected through a J-incision and it was found to be a benign schwannoma in pathology. Schwannoma are relatively rare tumor and even rarer in children. The incidence of such tumors and the management of our patients are discussed.

[J Indian Med Assoc 2019; 117: 29-30]

Key words : Schwannoma, Pediatrics, Histology, Surgery.

The head and neck region is a source of swelling of a wide range of pathological types. The commonest cause of neck swelling in children is reactive lymphadenopathy associated with upper respiratory tract infections. However, other types of swellings such as branchial, sebaceous and thyroglossal cysts are regularly encountered. We report an unusual swelling in a 14 year old boy with Schwannoma of the cervical vagus nerve mimicking Glomus tumor on a MRI scan.

CASE REPORT

A 14-year-old boy presented with a history of an asymptomatic swelling of the left side of neck since 6 months, which is slowly increasing in size. It was situated in the anterior triangle of the neck. The size at the time of admission was 4 x 4 cms. There was no history of hoarseness of voice, nasal regurgitation, syncopal attacks or associated pain. There was no history of trauma or fever. Examination revealed a firm; non pulsatile swelling that was mobile only in transverse plane. The carotids were palpable anterior to the swelling. FNAC revealed a vascular lesion, MRI scan showed a well circumscribed mass, 4 × 4 cm located in the lateral part of neck and was suggestive of a Glomus tumor (Fig 1), With Glomus tumor in mind the surgical procedure was planned.

The neck was explored by a J- incision along the upper part of neck (Fig 2), After dissection of carotids, Internal jugular vein, the tumor was found to arise from the left vagus nerve. The tumor was completely excised along with the sheath sacrificing the vagus nerve. Patient was discharged after 7 days. The histopathological exami-

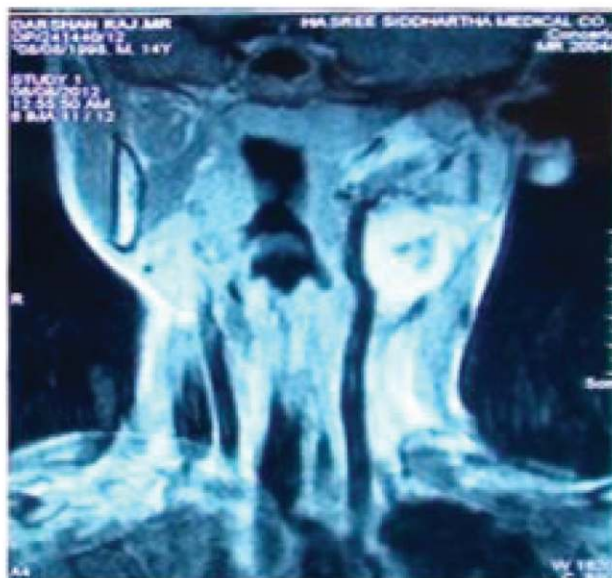


Fig 1 — MRI Scan of the neck showing the tumor

nation of the specimen revealed schwannoma. Postoperatively the patient has hoarseness of voice and is on speech therapy.

DISCUSSION

Paragangliomas are rare tumors. Approximately 10% of them arise from the vagus nerve. Till June 2000, only 95 schwannoma has been reported in the literature, with the majority of being in patients between 30 and 60yrs of age^{1,2}. Although neck swellings in children are common, the vast majorities are due to the reactive lymph nodes. Neurogenous tumors are relatively rare. In one reported series of pediatric neck masses, neurogenous tumors accounted for 2% of benign non-lymphadenomatons lesion. The commonest cause was sebaceous cysts (34%), followed by throglossal

Department of General Surgery, Sree Siddhartha Medical College, Hospital & Research Centre, Tumkur 572107

¹MS, Associate Professor and Corresponding author

²MS, Assistant Professor

³MS, DNB, Associate Professor

⁴MBBS, Postgraduate Student, Senior Resident

⁵MBBS, Postgraduate (MS) Student, Junior Resident

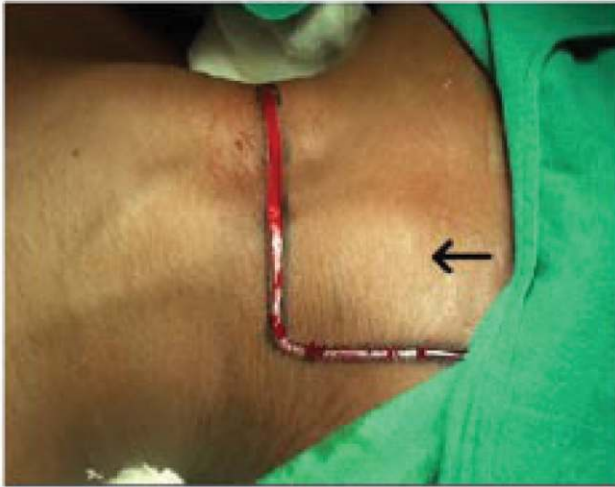


Fig 2 — Incision of the neck

cysts (13%), branchial remnants (9%) and dermoid (9%)³. A review of documented cases suggests that approximately 10% of schwannoma are diagnosed in patients less than 21 years of age^{4,6}. Schwannoma may be found in any part of the body but tend to occur in the head and neck region and the flexor surfaces of the upper and lower extremities. Between 25 and 45% of all reported schwannoma are found in the head and neck region.

These sites include the parapharyngeal space, neck, Para nasal sinuses, nasal and oral cavities, face, scalp, intracranial cavity and larynx^{7,8}. Reported cases of head and neck schwannoma in children include involvement in the nasopharynx and neck⁹ and larynx¹⁰. The lateral side of the neck is the commonest site of extra cranial schwannoma. Cranial nerves and sympathetic chain give rise to tumors in the medial half of the neck. The vagus nerve is the most commonly involved cranial nerve. The nerve of origin can be identified in only approximately one quarter of cervical schwannoma.

A preoperative diagnosis may be made with some certainty based on a high index of suspicion from the history of painless, pulsatile

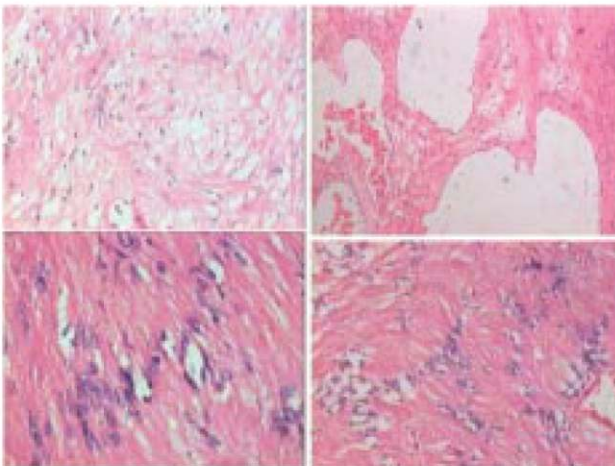


Fig 3 — Histopathological examination typically of schwannomas

swelling, characteristically mobile laterally but immobile vertically, reflecting its attachment to the vagus nerve. CT scan, MRI and angiography may obtain confirmation of the diagnosis. Incisional biopsy is unnecessary and contraindicated because of vascular nature of the lesion and the possibility of uncontrolled hemorrhage. It may also make removal of tumor mass difficult because of obliteration of tissue plane.

A schwannoma is a solitary and encapsulated tumor. Histologically, it exhibits two main patterns—Antoni A and Antoni B. Antoni A tissue is represented by a tendency towards palisading of the nuclei about a central mass of cytoplasm (Verocay bodies). In contrast, Antoni B tissue is a loosely arranged stroma in which the fibers and cells form no distinctive pattern. A mixed picture of both types can exist. Other typical features include necrosis, hemorrhage and cystic degeneration (Fig 3). Malignant change in the nerve sheath tumors in the head and neck is very rare.

Gross total resection remains the treatment of choice for these tumors. The capsule is gently and carefully dissected from the fascicles of the nerve. When it is necessary to debulk the tumor, the capsule is incised longitudinally to preserve the uninvolved fascicles. However as much as possible of the capsule should be removed to prevent recurrence. If the nerve or some of the fascicles cannot be salvaged, a split repair should be performed using the great auricular or sural nerve. In cases where it is not possible, vagus nerve is sacrificed along with the tumor. Hoarseness is nearly always present after resection and recovers in most cases. Other common complications include pharyngo-laryngeal anesthesia, aspiration and cranial nerves IX, XI and XII palsies, which may be transient or permanent.

CONCLUSION

Schwannomas of the head and neck are usually benign and slow growing tumors. They are most often diagnosed in adults but can also occur in children although not so often. Even in children, such tumors are relatively rare compared with other types of neck swellings. Surgical excision of schwannoma with or without sacrificing nerve results in complete cure with little likelihood of recurrence.

REFERENCES

- 1 Wilson JA, McLaren K, McIntyre MA, Von Haake NP, Maran AGD — Nerve sheath tumours of the head and neck. *Ear, Nose and Throat Journal* 1988; **67**: 103-10.
- 2 Hamza A, Fagan JJ, Weissman JL, Myers EN — Neurilemmomas of the parapharyngeal space. *Arch Otolaryngol Head Neck Surgery* 1997; **123**: 622-6.
- 3 Connolly AAP, Mackenzie K — Paediatric neck masses - a diagnostic dilemma. *The Journal of Laryngology and Otology* 1997; **111**: 541-5.
- 4 Das Gupta TK, Brasfield RD, Strong EW, Hajdu SI — Benign solitary Schwannomas (neurilemmomas). *Cancer* 1969; **24**: 355-66.