

## Pictorial CME

### Moya Moya Disease — A Rare Case of Stroke in Children

Sumi M Pillai<sup>1</sup>, Jayakrishnan M P<sup>1</sup>, Tanu Arora<sup>1</sup>, K Malcolm Jayaraj<sup>2</sup>, S Sakthivelayutham<sup>2</sup>, P R Sowmini<sup>2</sup>, M Sathish Kumar<sup>2</sup>, R Viveka Saravanan<sup>3</sup>, K Mugundhan<sup>4</sup>

A 13 year old boy admitted with weakness of right upper limb and lower limb and speech difficulty since 1 day. Neurological examination showed right hemiparesis with power -MRC grade of 2/5 and 4/5 in right upper limb and right lower limb respectively. MRI Brain (Fig a) showed acute infarct in left post central gyrus, corona radiata, posterior limb of internal capsule and insular cortex. MR angiogram revealed complete occlusion of supraclinoid segment of left internal carotid artery (ICA) with multiple collaterals. CT angiogram (Fig b) revealed complete occlusion of left ICA with reformation of left anterior cerebral artery and middle cerebral artery. Digital subtraction angiography (DSA) revealed narrowing of distal cavernous and supra clinoid segment of left ICA with multiple collaterals, flow of contrast into left posterior cerebral artery (PCA) via posterior communicating artery noted (fig c). Complete occlusion of M1 segment of left MCA with multiple adjacent collaterals noted. Right ICA and MCA were opacified and a diagnosis of moyamoya disease was made and patient was treated with antiplatelets and physiotherapy. Patient improved over a period of 4-6 weeks.

#### DISCUSSION

Moyamoya disease (MMD) is a type of chronic occlusive cerebrovascular disease. Its major characteristic is a steno-

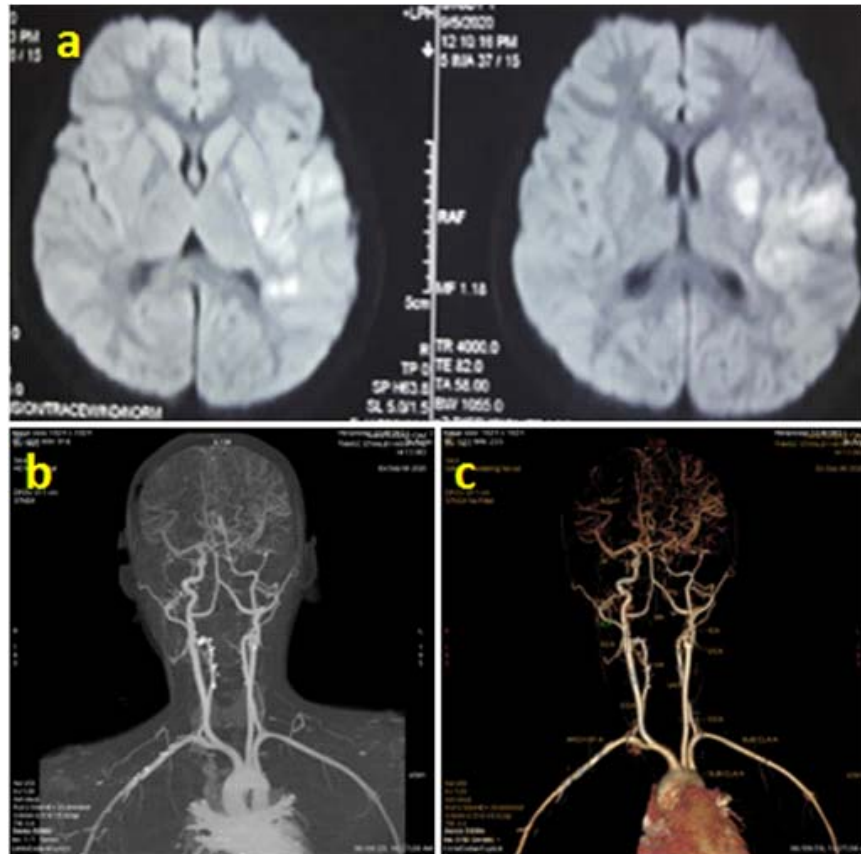


Fig 1 — (a) MRI DWI Image showing acute infarct in left post central gyrus, corona radiata, posterior limb of internal capsule and insular cortex; (b) CT angiogram Revealed complete occlusion of left ICA with reformation of left anterior cerebral artery and middle cerebral artery; (c) DSA revealed narrowing of distal left ICA with multiple collaterals and complete occlusion of left MCA. Right MCA and bilateral ACA and its branches were opacified

occlusive change at the end of the internal carotid artery (ICA), middle cerebral artery (MCA) and/or proximal anterior cerebral artery (ACA), which is accompanied by the formation of smoke-like abnormal blood vessels in the base of the skull in digital subtraction angiography (DSA).

The clinical signs of MMD mainly include two types: Cerebral ischemia and cerebral hemorrhage. These two types of symptom differ in their distribution between pediatric and adult patients. Most of the pediatric patients present with progressive cerebral ischemia, including transient cerebral ischemic attacks and cerebral infarctions. Mental

Department of Neurology, Stanley Medical College, Chennai 600001

<sup>1</sup>DM, Postgraduate Student

<sup>2</sup>MD, DM, Assistant Professor

<sup>3</sup>MD, DM, Associate Professor

<sup>4</sup>MD, DM, FRCP (G,L&Ire) FACP, FICP, Professor and Head

decline or seizures may be the first symptom in children. In half of the cases in adults, intracranial hemorrhage is the first symptom.

In 1996, Japan issued a guideline<sup>1</sup> for the diagnosis and treatment of Moyamoya disease, MMD) which suggests the following manifestations on cerebral angiography (i) Stenosis or occlusion at the end of the carotid artery, the proximal ACA and/or MCA; (ii) an abnormal vascular network in the vicinity of stenotic occlusion lesions in the arterial phase; and (iii) the above manifestations are bilateral.

In the 2012 guidelines<sup>2</sup>, cerebral angiography remains the gold standard for the diagnosis of MMD with the staging performed according to angiographic findings. The system most widely used for its evaluation is the Suzuki staging system, in which the cerebral angiographic findings of MMD patients are divided into 6 stages based on the progression degree of smog-like blood vessels.

The current drug treatment for in MMD only targets its clinical symptoms, including ischemia and hemorrhage, by exerting anti-coagulant or hemostatic effects.

The preventive effect of surgical revascularization treatment has been clinically demonstrated on ischemic events<sup>3</sup>. However, intra- and extra-cranial revascularization for the prevention of recurrence of bleeding in patients with hemorrhagic MMD is controversial. Surgical revascularization of MMD includes 3 types: Direct revascularization, indirect revascularization and combined revascularization. In the direct revascularization surgery, the most common

method is superficial temporal artery-MCA anastomosis.

MMD is an important cause of cerebral stroke in pediatric and adult patients. A definitive diagnosis of MMD must be made as soon as possible, so that with treatment relatively long-term prognosis can be achieved. Surgery remains an important treatment for MMD, but an individualized clinical treatment strategy should be selected according to the condition of each patient. This case report serves to emphasize the need for a high index of suspicion to diagnose this rare stroke.

#### REFERENCES

- 1 Fukui M — Guidelines for the diagnosis and treatment of spontaneous occlusion of the circle of Willis (moyamoya' disease). Research committee on spontaneous occlusion of the circle of Willis (moyamoya disease) of the ministry of health and welfare, Japan. *Clin Neurol Neurosurg* 1997; **99(Suppl 2)**: S238–S240. doi: 10.1016/S0303-8467(97)00082-6.
- 2 Research Committee on the Pathology and Treatment of Spontaneous Occlusion of the Circle of Willis; Health Labour Sciences Research Grant for Research on Measures for Intractable Diseases: Guidelines for diagnosis and treatment of moyamoya disease (spontaneous occlusion of the circle of Willis) *Neurol Med Chir (Tokyo)* 2012; 52: 245-66. doi: 10.2176/nmc.52.245.
- 3 Fujimura M, Tominaga T — Lessons learned from moyamoya disease: Outcome of direct/indirect revascularization surgery for 150 affected hemispheres. *Neurol Med Chir (Tokyo)* 2012; 52: 327-332. doi: 10.2176/nmc.52.327.

**Submit Article in JIMA - Online**

**See website : [https:// onlinejima.com](https://onlinejima.com)**

**Any quaries : (033) 2237-8092, +919477493027; +919477493033**