

Student's Corner

Become a Sherlock Homes in ECG

M Chenniappan¹

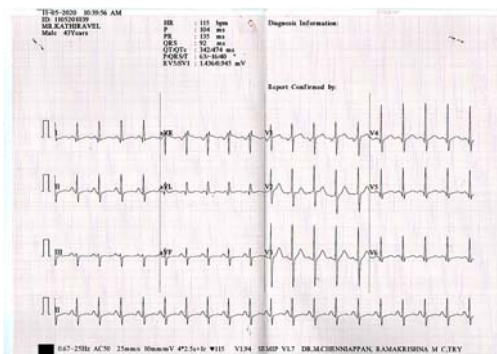
Series 5 :

ECG

“Watch the watch”

This ECG of a 53 years old Diabetic male complaints of chest pain.

1. Describe the ECG changes?
2. Why is this clue?
3. What are practical implications?



• If the transition occurs after V4, this is called clockwise rotation (Fig 59a).

Causes of clockwise rotation were:

- intraventricular conduction abnormalities secondary to myocardial degeneration
 - right ventricular heart disease
- shift of the septum to the left
 - dilated cardiomyopathy
- shift of the whole heart
 - pulmonary emphysema
 - vertical heart (usually thin and tall persons)

Answers :

ECG FINDINGS

ECG shows sinus tachycardia, Tall R wave in V1, Left atrial abnormality and normal axis. There is also prominent septal q in V5,V6 as well as L1 and avL. There are many causes for Tall R wave in V1 like RVH,RBBB, Dextrocardia, Type A WPW pattern, Hypertrophic Cardiomyopathy, Duchene Muscular Dystrophy,etc. In our patient the cause of tall R wave is likely to be due to counter clockwise rotation. This is unlikely to be Asymmetrical Septal Hypertrophy because there are no deep narrow septal q waves in V5,V6. Counter clockwise rotation is diagnosed if equiphase zone in chest leads shifted to right. In our ECG, equiphase zone is in V1 and V2.

Description about clockwise and counter clockwise rotation.

- Clockwise and counterclockwise rotation refer to a change in the electrical activity in a horizontal plane through the heart.

- Imagining the observer standing at the feet of the patient who is in bed.

- If the electrical activity of the heart has turned more to the right side of the patient this is called *counter clockwise rotation*.

- * If the electrical activity of the heart has turned more to the left side of the patient this is called *clockwise rotation*

- Clockwise and counterclockwise rotation can be assessed only in the chest-leads (V1 - V6).

- Normally the R wave amplitude increases from V1 to V5. Around V3 or V4 the R waves become larger than the S waves and this is called the ‘transitional zone’.

- If the transition occurs at or before V2, this is called counterclockwise rotation.

- pulmonary emphysema
- vertical heart (usually thin and tall persons)

Causes of counterclockwise rotation were:

- electrical shift to the right
 - right ventricular hypertrophy
 - WPW Syndrome
 - Posterior myocardial infarction
 - Left post. fascicular block
- shift of the septum to the right
 - hypertrophic cardiomyopathy

The deep terminal negative component of P in V1 is suggestive of left atrial abnormality and so left ventricular dysfunction has to be excluded.

Clue:

The clue is about the Counter “clock”wise rotation as the cause of Tall R wave in V1. Observing or watching the watch (clock) will give the diagnosis.

Practical implication :

Counterclockwise rotation, the most prevalent QRS transition zone pattern, demonstrated the lowest risk of CVD and mortality, whereas clockwise rotation was associated with the highest risk of heart failure and non CVD mortality. These results have implications on how to interpret QRS transition zone rotation when ECG was recorded.

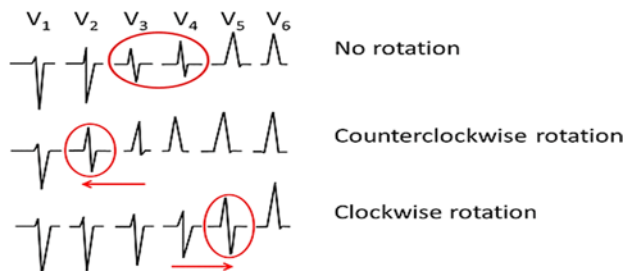


Fig 59a : Showing ecg patterns of various rotations in chest leads

¹Adjunct Professor, Dr MGR Medical University, Tamilnadu; Senior consultant cardiologist, Tamilnadu; Ramakrishna Medical Centre, Apollo Speciality Hospital, Trichy