

Pictorial CME

A 50 year old woman with personality change

N.Reema*, Dr S.Bhagyabati Devi**

Take home messages:-

Even in the era of HAART, AIDS dementia complex is still a possibility
 HIV positive patients with cognitive dysfunction or motor abnormalities should have an early CNS imaging study
 Clinicians dealing with PLHA should be aware of the long term neurological complications

Keywords-AIDS Dementia Complex HIV associated dementia HAART therapy

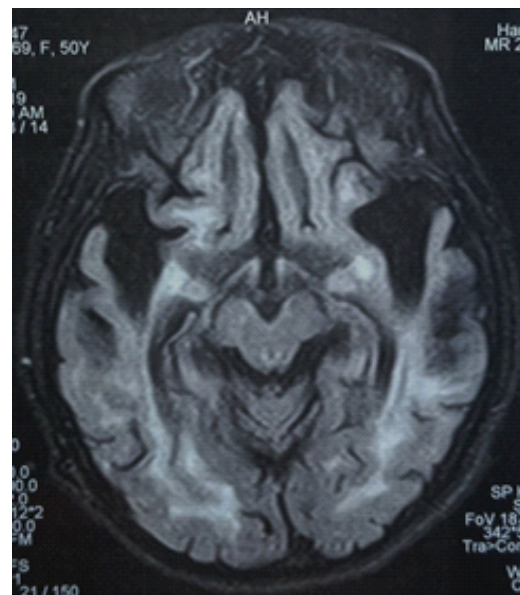
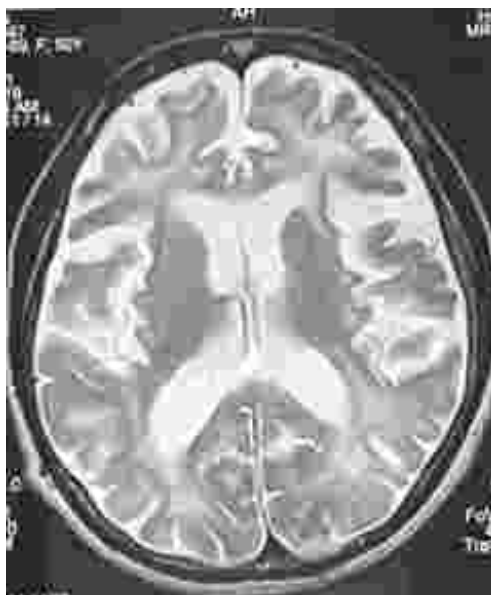A 50 year old HIV positive female presented with forgetfulness (dementia), inability to recognize her relatives, tremor of the hands, inability to hold objects, an episode of aggressiveness and violent behaviour along with focal seizures and emotional liability. Her laboratory investigations including CSF examination were all within normal limits. Her CD4 count was 488 with a viral load of 175 copies/ml. MRI images of her brain are given here (figures 1 and 2).

1. What is the probable diagnosis?
2. What are the criteria for diagnosis of this condition?
3. What is the treatment?

Answers:-

1. HIV associated dementia (HAD)/AIDS dementia complex (a part of the spectrum of HIV associated neurocognitive disorder-HAND)

2. AIDS Dementia Complex (ADC) is a subcortical dementia. HAD incidence is 10.5/1000 patients per year and typically presents with loss of attention, concentration, slowing of motor execution with behavioural change. The American Academy of Neurology (AAN) criteria for HAD are 1) abnormality in at least two cognitive (non-motor) functions causing work, daily activities and 2) either motor function or specified psychiatric or psychosocial functions alterations (e.g., lack of motivation, emotional liability, social behavioural change).
3. Treatment wise, HAART therapy has decreased the occurrence of HAD significantly. Substituting ART drugs which can cross blood brain barrier, eg; Zidovudine, stavudine, abacavir, nevirapine, indinavir and lamivudine to lesser extent, should be included.



* SR,
 ** Professor, Dept. of Medicine, RIMS, Imphal

Editor: Rudrajit Paul

References:-

1. Clifford DB, Ances BM. HIV-associated neurocognitive disorder. Lancet Infect Dis. 2013;13(11):976-986. Doi:10.1016/S1473-3099(13)70269-X