

Case Report

A rare case of Ocular Dirofilariasis

D N Prakash¹, K Satish², Madhumita Gopal³, Uma Balakrishnan⁴, Hemapriya³

A middle aged male patient from Mandya presented with pain and a swelling over the nasal aspect of the bulbar conjunctiva lasting for a few days with similar episodes over the past 3 months. On slit lamp examination a mobile thread like worm was observed beneath the conjunctiva. Surgical removal of a live worm was done successfully and sent for histopathological examination, where it was identified to be *Dirofilaria repens*. Surgical excision of subtenon's dirofilariasis is safe and curative precluding the need for further systemic antihelminthics.

[J Indian Med Assoc 2019; 117(10): 40]

Key words : *Dirofilaria*, Ocular.

A middle aged male patient hailing from Mandya, Karnataka, with no history of travel presented with pain and swelling over the nasal aspect of the bulbar conjunctiva lasting for a few days, with similar episodes over the past 3 months. He had consulted a local doctor where he was suspected to have a foreign body granuloma and was put on topical medication. On slit lamp examination a mobile thread like worm was observed beneath the conjunctiva in the region of the swelling. Rest of the ocular examination was within normal limits and his visual acuity was 6/6 in both eyes. The patient was taken up for surgery. A live worm measuring about 9.5 cm was removed successfully from the subtenon's space and sent for identification. The worm was identified to be *Dirofilaria repens* on the basis of microscopic examination and histopathology. The patient had no systemic symptoms or signs and the peripheral smear was negative for microfilaria. Following removal the patient had no further complaints (Figs 1-3).

DISCUSSION

Dirofilariasis is a form of zoonotic filariasis caused by the nematode worm, *Dirofilaria*. It is transmitted to humans by the bite of *Aedes*, *Culex* or *Anopheles* mosquitoes. Dogs, cats, foxes and raccoons are the definitive hosts while humans are accidental hosts. Dirofilariasis is often reported from European countries surrounding the Mediterranean particularly from Italy. The other countries that have reported these infections are France, Greece and Israel. In India, subcutaneous Dirofilariasis is rare and most cases have been reported from

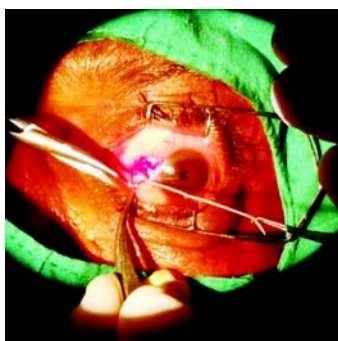


Fig 1 — Worm being pulled out of the Subtenon's space

Kerala, Karnataka and Tamil Nadu. Ocular Dirofilariasis is a form of subcutaneous Dirofilariasis caused most often by *Dirofilaria repens*. Systemic involvement may be subcutaneous, pulmonary or generalized. Ophthalmic involvement may be periorbital, subconjunctival, subtenon or intraocular. Such lesions are usually associated with moderate to severe inflammation.

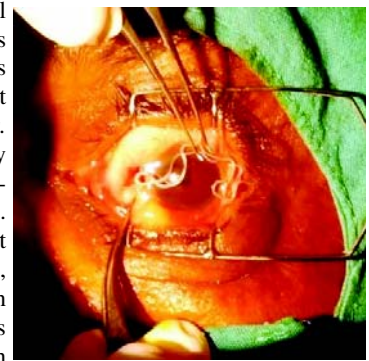


Fig 2 — Extracted live worm once corneal surface

The symptoms of the disease vary and include local pain,

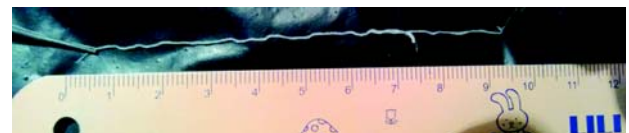


Fig 3 — The worm measured about 9.5 cm

proptosis, diplopia, palpebral and conjunctival edema, redness, foreign body sensation and impaired vision. Surgical removal of the worm is curative and technically a simple procedure.

CONCLUSION

Ocular dirofilariasis is a rare condition. Although the symptoms can be severe, treatment by surgical removal is simple and precludes the need for antihelminthic treatment.

REFERENCES

- Mittal M, Sathish KR, Bhatia PG, Chidamber BS — Ocular dirofilariasis in Dubai, UAE. *Indian J Ophthalmol* 2008; **56(4)**: 325-6.
- Sathyan P, Manikandan P, Bhaskar M, Padma S, Singh G, Appalaraju B — Subtenons infection by *Dirofilaria repens*. *Indian J Med Microbiol* 2006; **24(1)**: 61-2.
- Janjetovijæ Z, Arar ZV, Paradzik MT, Sapina L, Bitunjac M, Lojen G, *et al* — Ocular dirofilariasis : a case report. *Acta Med Croatica* 2010; **64(1)**: 41-5.

Department of Ophthalmology, Krishnarajendra Hospital, Mysore Medical College and Research Institute, Mysore 570001

¹MS (Ophthalmol), Assistant Professor and Corresponding author

²MS (Ophthalmol), Associate Professor

³MBBS, DOMS, Resident

⁴MBBS, MS, Resident