

## Review Article

# A comparative study of onlay and pre-peritoneal mesh repair in the management of ventral hernias in our hospital

Tapan A Shah<sup>1</sup>, Yogendra S Modi<sup>2</sup>, Mukesh S Suvera<sup>3</sup>, Rajesh H Parmar<sup>4</sup>,  
Khyati C Vaja<sup>4</sup>, Jemish B Patel<sup>4</sup>, Shireesh M Ninama<sup>4</sup>, Sachi P Sankhala<sup>4</sup>

A Ventral hernia includes both spontaneous and incisional hernias after an abdominal operation. Meshplasty can be onlay (over anterior rectus sheath) or sublay (pre-peritoneal). Controversy exists regarding use of the type of either meshplasty, due to differences in ease in performing the surgery, time of surgery, complications occurring in post-operative period and recurrence. Aim of our study was to compare the outcome of onlay versus sublay mesh repair for ventral hernia. A total number of 180 patients with ventral hernias (with defect size  $\leq 4$  inches), admitted in surgery dept. in Smt SCL General Hospital & Sheth VS Hospital, Ahmedabad from July 2016 to June 2017, were divided into two groups; A- onlay mesh repair and B- sublay mesh repair. Patients were evaluated for operating time, postoperative seroma formation, wound infection, drain duration, post-op hospital stay and recurrence of symptoms. Among 180 patients, 90 patients underwent onlay and 90 patients underwent pre-peritoneal meshplasty. Out of 90 cases of onlay, only 28 cases took  $>1$  hour for operating. Out of 90 cases of pre-peritoneal meshplasty, hospital stay was  $> 5$  days for 11 cases and seroma was found in 3 cases and wound infection was found in 4 case and post-operative pain score was less in most cases. On analysis of results and five variables, pre-peritoneal mesh repair is comparatively good option even though duration of surgery is longer than onlay mesh repair.

[J Indian Med Assoc 2019; 117: 25-8]

**Key words :** Ventral hernia, onlay, pre-peritoneal, mesh repair.

A ventral hernia is a bulge through abnormal opening in the anterior abdominal muscles. Ventral hernias include incisional hernia through previous surgical incision site, umbilical and paraumbilical hernia, epigastric hernia<sup>1</sup>. Repair of ventral hernias with mesh as opposed to suture has substantially improved long-term outcomes. However, many studies demonstrate an increased risk for wound complications with mesh placement including infections, seromas, and mesh erosions<sup>2,3</sup>. Mesh can be placed over anterior rectus sheath (onlay) or pre-peritoneal space. With onlay repair, skin flaps must be created, which increases the risk of wound complications and mesh infection<sup>2,4</sup>. The risks of postoperative complications are affected by where the mesh is placed. For example, mesh exposed to intra-abdominal contents potentially increases the risks of adhesions, bowel obstruction, and fistula formation<sup>4,5,10</sup>.

Pre-peritoneal space potentially protects the mesh from both superficial wound complications and intraperitoneal contents. In addition, it also allows for load-bearing tissue in-growth from two directions<sup>5</sup>. Due to excess mobiliza-

tion of fat and disruption of perforators immediate post-operative complications like seroma and wound infection rate will be more in onlay mesh technique<sup>3,5</sup>. This comparative study was to focus on advantage and disadvantage of two types of meshplasty and to provide information regarding benefits of one over another<sup>6</sup>.

### *Aims and Objectives of the Study :*

The aim of this study was to compare the outcome of the onlay versus sublay mesh repair for ventral hernia.

#### MATERIALS AND METHODS

A combined prospective and retrospective study was carried out on 180 patients of ventral hernias (epigastric, umbilical, para-umbilical and incisional hernias excluding very large hernias with defect more than 4 inches) admitted in the Department of Surgery, Smt SCL Hospital and VS Hospital, Smt NHL Municipal Medical Collage, Ahmedabad over a period of 1 year from July-2016 to June-2017. All patients were grouped alternatively as ;

- Group A : Onlay mesh plasty (mesh over the anterior rectus sheath, 90 cases)

- Group B : Sublay mesh plasty(pre-peritoneal, 90 cases)

#### OBSERVATIONS

In both the groups were made with regards to duration of surgery, postoperative complications like seroma formation, wound infection, duration of drain placement, postoperative stay and recurrences, if any.

Department of General Surgery Smt NHL Municipal Medical Collage, Ahmedabad 380006

<sup>1</sup>MS, Assistant Professor and Corresponding author

<sup>2</sup>MS, Professor & Head

<sup>3</sup>MS, Associate Professor

<sup>4</sup>3rd year resident

• All the patients were given 1gm 3rd generation cephalosporin antibiotic preoperatively at the time of induction and continued till the 5th postoperative day twice daily, and then changed to oral antibiotic (cefexime/ amoxicillin + clavulanic acid) twice daily for the next 5 days. Early mobility was strongly encouraged as cultural attitudes towards surgery in the setting are prohibitors to early ambulation for several days in postoperative period<sup>7,8</sup>.

Follow up every monthly for 12 months was done to see late wound complications like sinus, neuralgia and recurrence of hernia etc. Conclusions were drawn using unpaired student t-test.

• **Duration of Study :** 1 year (July-2016 to June-2017)  
Sample Size : 180.

• **Type of Study :** A Combined Prospective and Retrospective study.

• **Inclusion Criteria :** All patients of age group more than 18 years who were presented with ventral hernias (epigastric, umbilical, para-umbilical and incisional hernias) and undergone surgery, were taken and analysed.

• **Exclusion Criteria :** (1) Patients, less than 18 years, (2) Groin hernia, (3) Divarication of recti, (4) Patients, medically not fit for surgery, (5) Patients, not giving consent.

### *Surgical Technique :*

(A) **Onlay mesh repair :** The onlay repair was done under general anaesthesia with skin incision over the bulge or the defect. The hernia sac was clearly dissected and the contents were removed and the margins of the defect were held by Kocher forceps. The sac was dealt with and its contents were reduced into the abdominal cavity. With non-absorbable suture, the defect in the linea alba was closed and a proline mesh of adequate size was placed on the rectus sheath and fixed with stitches<sup>9,10</sup>. Hemostasis was secured. A dose of broad-spectrum antibiotic was given prior to anaesthesia.

(B) **Sublay mesh repair :** The principles of the pre-peritoneal or sublay mesh repair included two main steps; mesh placement deep to the recti muscles and mesh extension well beyond the hernia defect. After the sac was being dissected and delineated, the defect is opened and the pre-peritoneal plane is created between the posterior rectus sheath and the rectus muscle for the placement of the mesh. The posterior rectus sheath along with the peritoneum is closed with zero prolene suture.

A proline mesh tailored to the size is placed in the already created plane behind the recti. The mesh is secured with few interrupted 2-0 polypropylene sutures. A suction drain is placed over the mesh. The anterior rectus sheath is closed with continuous 1-0 polypropylene sutures<sup>9,10</sup>. Another drain is placed in the subcutaneous plane and the skin closed. Drains were removed when drainage was <20 ml in 24 hours.

All the patients were given 1gm 3rd generation cephalosporin antibiotic preoperatively at the time of induction

and continued till the 5th postoperative day twice daily, and then changed to oral antibiotic (cefexime / amoxicillin + clavulanic acid) twice daily for the next 5 days. The hospital stay of the patients was also recorded down (Fig 1).

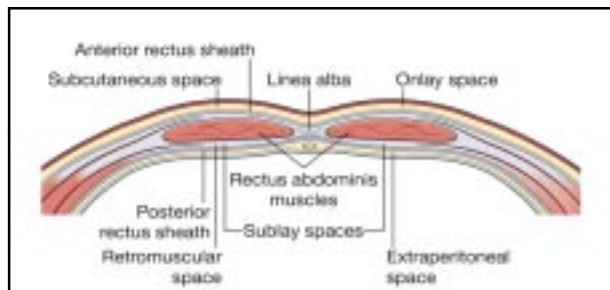


Fig 1 — Showing various layers into which mesh is placed in ventral hernia repair

### **RESULTS**

Among the 180 patients, 90 patients underwent onlay and 90 patients underwent pre-peritoneal mesh repair. Out of 90 cases of onlay, only 28 cases took more than one hour for operating. Out of 90 cases of pre-peritoneal mesh repair, hospital stay was more than five days for only 11 cases and seroma was found in only 3 cases and wound infection was found in only 4 case and postoperative pain score was less in most cases.

### *Percentage Distribution of Ventral Hernias:*

In this study of 180 patients of ventral hernia, the most common type of ventral hernia was incisional hernia (47.22%). Epigastric hernia was the least common type (05%) (Table 1).

Type of Hernia	Frequency	Onlay	Sublay
Umbilical	63 (35%)	27	36
Paraumbilical	23 (12.78%)	11	12
Incisional	85 (47.22%)	45	40
Epigastric	09 (05%)	07	02
Total	180	90	90

### *Age and Sex Distribution :*

Out of 180 patients, 98 patients were male and 82 patient were female. Most of cases are from middle age group (Table 2).

Age group (in years)	Male	Female	Total	Percent
18 to 30	13	12	25	13.9 %
30 to 40	30	11	41	22.8 %
40 to 50	17	24	41	22.8 %
50 to 60	30	26	56	31.1 %
> 60	08	09	17	9.4 %
Total	98	82	180	100%

### *Postoperative Course :*

The most common complication observed was seroma formation in 26 patients. Out of 26 patients, 3 were in pre-peritoneal and 23 in onlay mesh repair group (Table 3). This complication was managed with seroma drainage. Onlay technique had more of seroma formation, due to the fact that onlay techniques require significant subcutaneous dissection to place the mesh, which can lead to de-

vitalized tissue with seroma formation or infection.

Table 3 — Postoperative complications

Complications	Group A (Onlay) (90)	Group B (Sublay) (90)	Total (180)
Wound infection	23 (25.5%)	04 (4.4%)	27 (15%)
Seroma formation	23 (25.5%)	03 (3.3%)	26 (14.4%)
Flap necrosis	02 (2.2%)	00 (0.0%)	02 (1.1%)
Recurrence in 1 year	03 (3.3%)	00 (0.0%)	03 (1.66%)

Wound infection was found in 27 cases. Out of these 4 in pre-peritoneal group and 23 were in onlay group (Table 3). These patients were treated with appropriate antibiotics and regular dressing. No patient required removal of mesh because the infection was superficial and responded well to antibiotics.

Chronic pain was a complaint of 18 patients in all. Out of these 15 were in onlay group while 3 in pre-peritoneal mesh repair group. The reason for chronic pain in onlay mesh repair may be because mesh is placed below subcutaneous plane over

the muscle and sutured over it that causes chronic muscle irritation and because of the fact that the closure is in tension (Table 4).

Table 4 — Postoperative pain

Postoperative pain	Group A (Onlay) (90)	Group B (Sublay) (90)
0 (no pain)	00 (00%)	00 (00%)
1-3 (mild)	05 (5.6%)	33 (36.6%)
4-7 (moderate)	46 (51.1%)	55(61.1%)
7-10 (severe)	39 (43.3%)	02 (2.3%)

Mean duration of hospital stay post operatively in sublay group was 4.8±1.51 days, whereas it was 6.68±1.46 days in onlay group (Table 5).

Table 5 — Duration of hospital stay

Duration of hospital stay	Group A (Onlay)	Group B (Sublay)
<5 days	07 (7.78%)	79 (87.78%)
> 5 days	83 (92.22%)	11(12.22%)
Total	90	90

**Duration of Surgery :**

In group A (onlay), the operative time ranged from 50 to 90 minutes with a mean operative time of 67.04±13.19 minutes, while in group B (sublay), the operative time ranged from 60 to 140 minutes with a mean operative time of 93.26±24.94 minutes (Table 6).

Table 6 — Duration of surgery

Duration of surgery	Group A (Onlay)	Group B (Sublay)
<1 hour	62 (68.9 %)	00 (00%)
>1 hour	28 (31.1 %)	90 (100%)
Total	90	90

**DISCUSSION**

Ventral hernia in the anterior abdominal wall includes both spontaneous and, most commonly, incisional hernias after an abdominal operation. Small hernias less than 2½ cm in diameter are often successfully closed with primary tissue repairs. Primary tissue repair is associated with higher unacceptable recurrence rate, now-a-days, tension free mesh repair is ideal hernia repair. Mesh placement in the pre-peritoneal, retro muscular sublay position with overlapping the hernia defect in all directions was intro-

duced in the late 1980s<sup>11</sup>. The refinement of sublay technique decreased the recurrence rates and gave better outcome making it to be declared the standard of care of ventral hernias<sup>11</sup>.

Most important comparable factors are duration of hospital stay, postoperative complications, recurrence and resume to routine work<sup>12-14</sup>. At the end of analysis, results mentioned above are compared. Based on the above results, duration of surgery was less in case of onlay mesh repair compared to pre-peritoneal mesh repair. In case of onlay mesh repair, 68.9% of cases took less than an hour for operating. But 100% of pre-peritoneal mesh repair took more than an hour for operating. In 87.78% pre-peritoneal mesh repair, hospital stay was less than five days. In 92.2% of onlay mesh repair, hospital stay was more than five days. 25.5% of onlay mesh repair cases developed seroma. But only 3.3% of pre-peritoneal mesh repair developed seroma. 25.5% of onlay mesh repair cases developed wound infection. But only 4.4% of pre-peritoneal mesh repair cases developed wound infection. Postoperative pain score was 4 and 5 for more than 60% of the pre-peritoneal mesh repair cases. But pain score was more than 5 in most of the cases in onlay mesh repair.

**Conclusion :**

Sublay mesh repair is a good alternative to onlay mesh repair that may be applicable to all forms of ventral hernia. The mesh related overall complication rate is low in sublay mesh repair such as drainage time, seroma formation and wound infection as well as the low recurrence rate.

**REFERENCES**

- 1 Björk D, Cengiz Y, Weisby L, Israelsson LA — Detecting Incisional Hernia at Clinical and Radiological Examination. *Surg Technol Int* 2015; **26**: 128-31.
- 2 Fortelny RH, Baumann P, Thasler WE, Albertsmeier M, Riedl S, Steurer W, Kewer JL, Shamiyeh A — Effect of suture technique on the occurrence of incisional hernia after elective mid-line abdominal wall closure: study protocol for a randomized controlled trial. US National Library of Medicine National Institutes of Health. *Trials* 2015; **16**: 52. doi: 10.1186/s13063-015-0572-x.
- 3 SSAT patient care guidelines — Patient Care Committee, Society for Surgery of the Alimentary Tract. Surgical repair of incisional hernias. *J Gastrointest Surg* 2004; **8**: 369-70.
- 4 Timmermans L, de Goede B, van Dijk SM, Kleinrensink GJ, Jeekel J, Lange JF — Meta- analysis of sublay versus onlay mesh repair in incisional hernia surgery. *Am J Surg* 2014; **207**: 980-8.
- 5 Rajesh Godara, Pardeep Garg, Hans Raj, Sham L Singla — Comparative evaluation of "Sublay" versus "Onlay" meshplasty in ventral hernias. *Indian Journal of Gastroenterology* 2006; **25**: 222-3.
- 6 Majid HJ, Dar HM, Shafi M — Ventral incisional hernias mesh versus non-mesh repair, eleven years experience at Shaikh Zayed Hospital, Lahore. *Professional Med J* 2011; **18**: 228-32.
- 7 Salamone G, Licari L, Agrusa A, Romano G, Cocorullo G, Gulotta G — Deep seroma after incisional hernia repair. *Ann Ital Chir* 2015; **12**: 86(epub).

- 8 Holihan JL, Alawadi Z, Martindale RG, Roth JS, Wray CJ, Ko TC, Kao LS, Liang MK — Adverse Events after Ventral Hernia Repair: The Vicious Cycle of Complications. *J Am Coll Surg* 2015; **221**: 478-85. doi: 10.1016/j.jamcollsurg.2015.04.026. Epub 2015 May 9.
- 9 Sabiston DC, Jennifer W Harris, B Mark Evers, Mark A Malangoni — Sabiston Textbook of Surgery: The Biological Basis of Modern Surgical Practice: first south asia edition: Elsevier Saunders:chapter. 44 hernias, 1106-13;
- 10 Robert M Zollinger Jr, Robert M Zollinger Sr Zollinger's — Atlas of Surgical operations. Mc Graw Hill publications, eight edition 2003; 406-9.
- 11 Chelala E, Baraké H, Estievenart J, Dessily M, Charara F, Allé JL — Long-term outcomes of 1326 laparoscopic incisional and ventral hernia repair with the routine suturing concept: a single institution experience. *Hernia*, 2015 Jun 21. (Epub ahead of print).
- 12 Ibrahim AH, El-Gammal AS, Heikal MM — Comparative study between 'onlay' and 'sublay' hernioplasty in the treatment of uncomplicated ventral hernia. *Menoufia Med J* 2015; **28**: 11-6.
- 13 Goda El-Santawy HM, El-Sisy AA, El-Gammal AS, El-Kased AF, Sultan HM — Evaluation of retromuscular mesh repair technique for treatment of ventral incisional hernia. *Menoufia Med J* 2014; **27**: 226-9.
- 14 Elseesy A, Balba MA, Badr M, Latif MA. Retormascular Preperitoneal *versus* traditional onlay mesh repair intreatment of incisional hernias. *Menoufiya Med J* 2008; **21**: 209-20.
- 15 Novitsky YW, Porter JR, Rucho ZC, Getz SB, Pratt BL, Kercher KW, *et al* — Open preperitonealretrofascial mesh repair for multiply recurrent ventral incisional hernias. *J Am Coll Surg* 2006; **203**: 283-9.
- 16 Umer A, Ellner S — Commentary: How Long Do We Need to Follow-Up Our Hernia Patients to Find the Real Recurrence Rate? *Front Surg* 2015; **2**: 50.
- 17 Hameed F, Ahmed B, Ahmed A, Dab RH, Dilawaiz — Incisional Hernia Repair by Preperitoneal (Sublay) Mesh Implantation. *APMC* 2009; **3**: 27-31.
- 18 Oh T, Hollands MJ, Langcake ME, Parasyn AD — Incisional hernia repair: Retrospective review and early experience of laparoscopic repair. *Surg* 2004; **74**: 50-6.
- 19 Kurzer M, Kark A, Selouk S, Belsham P — Open mesh repair of incisional hernia using a sublay technique: long term followup. *World J Surg* 2008; **32**: 31-6.
- 20 Stoppa RE — The treatment of complicated groin and incisional hernias. *World J Surg* 1989; **13**: 545-54.
- 21 Mahabhaleswar B, Santosh S — Preperitoneal mesh repair of incisional hernia. *Ind J Surgery* 2007; **69**: 95-8.
- 22 Gray SH, Hawn MT, Itani KM — Surgical progress in inguinal and ventral incisional hernia repair. US National Library of MedicineNational Institutes of Health. *Surg Clin North Am* 2008; **88**: 17-26, vii. doi: 10.1016/j.suc.2007.11.007.
- 23 Gleysteen JJ — Mesh-reinforced ventral hernia repair: Preferencefor 2 techniques. *Arch Surg* 2009; **144**: 740-5.
- 24 Saeed N, Iqbal SA, Shaikh BA, Baqai F — Comparison betweenonlay and sublay methods of mesh repair of incisional hernia. *J Post Med Inst* 2014; **28**: 400-3.
- 25 Aoda FS, Ibrahim AS — Sublay versus onlay mesh repair of ventral hernia. *QMJ* 2013; **9**: 208-13.