

## Case Report

# A wandering foreign body — ingested fish bone migrating to thyroid gland

Sunil Deshmukh<sup>1</sup>, Kalpana Patil<sup>2</sup>, Shrinivas Chavan<sup>1</sup>, Chaya Diwan<sup>3</sup>

An interesting case of an accidentally ingested foreign body ie, a sharp fish bone which has travelled to the left lobe of thyroid gland without causing any complication like oesophageal perforation or tear is reported here. Many People frequently eat fish as their food and accidentally fish bone gets embedded in either tonsils or throat which can be removed safely by an ENT surgeon. Many times it usually passes through the gastrointestinal tract without any complication, but here in our case when pt. came to us for the first time with Complaints of pain in throat at that time she was having no radiological and endoscopic evidence of FB and hence was send home but the same pt.came to us after 12 days with left lobe thyroid swelling which radiologically showed evidence of a radio opaque FB which was removed successfully by opening left thyroid lobe without doing lobectomy. The incidence of such type of complication without any mishap is very rare, hence we are reporting this case.

[J Indian Med Assoc 2019; 117: 34-5]

**Key words :** Fish bone, foreign body, oesophagus, thyroid gland.

### CASE REPORT

Esophageal penetration resulting from foreign body ingestion is uncommon, with the incidence reported to be between 1% and 4%. A wide variety of objects were retained in the esophagus but fish bones were the most common (60%) and chicken bones the second most common (16%). Owing to their fine, linear and sharp structure fish bones have tendency to stick and penetrate the mucosa, which occasionally can lead to severe complications. Prompt recognition and retrieval of ingested fish bones can reduce the morbidity and mortality.

A middle aged female of 40 years s came to us with chief complaints of :- A/H/O Foreign body (? Fish Bone) ingestion 12 days back, C/O difficulty in swallowing and C/O swelling (lump)over left side of neck x 5 days. She gave H/O accidental ingestion of fish bone 12 days back. So she presented to our emergency department with C/O pricking sensation in throat and dysphagia and some pain during swallowing. She was again presented in emergency deptt. with C/O swelling over left side of neck since 5 days and pain during swallowing and over the swelling (lump) also (Fig 1).

There was No H/O Fever, Headache, Cough with or without expectoration. No H/O Blood in Sputum or Vomitus.- No H/O Drooling of Saliva.- No H/O Chocking sensation in chest.- No H/O Difficulty in breathing.- No H/O Nausea, Vomiting. There was no significant H/O any major disease like DM, TB, or recurrent sinus or throat infections.

L/E : A swelling over anterior neck on left side measuring approximately 2 cm by 2 cm, smooth surface, with normal skin over it, ill defined margins, tender firm swelling moving on deglutition,

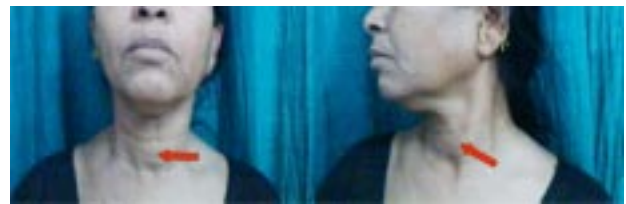

Fig 1 — Showing lump in front of neck (Lt) side of Preoperative photograph of patient

but not with protrusion of tongue, non pulsatile and non reducible.

### INVESTIGATIONS

#### Haematological —

- Hemoglobin- 11.2 gm %. Total leucocyte count: 14,000/mm<sup>3</sup>
- Differential leucocyte count: P 85 L 12 M 03 L 00. Platelet count: 2.1 lakh/mm<sup>3</sup>. Random blood sugar: 126 mg%
- USG Neck showed A linear hyperechoic foreign body is noted in a 4x2.8 cms sized collection in left paratracheal region adjacent to left lobe of thyroid gland (Figs 2&3).

#### CT Neck Findings —

- Hypodense lesion of size 4.5 x 1.8 cms noted adjacent to the heterogeneously appearing left lobe of thyroid with hyperdense linear structure within S/O? Foreign body. The above lesion is at the level of C5-C6 vertebrae. Right lobe of thyroid normal.
- Parotid glands appear normal. Both submandibular glands appear normal.

**Provisional Diagnosis :** A radio-opaque FB in neck? in left lobe of thyroid gland.

- Final Diagnosis : Foreign body oesophagus migrating to left lobe of thyroid .
- Treatment : systemic antibiotics followed by surgical exploration.

#### Surgery —

- Under GA, under AAP, PPD.

Department of Otolaryngology, Government Medical College & Hospital, Aurnagabad 431005

<sup>1</sup>MS (ENT), Associate Professor and Corresponding author

<sup>2</sup>MS (Anatomy), Assistant Professor of Anatomy, Government Medical College & Hospital, Aurnagabad 431005

<sup>3</sup>MS (Anatomy), Professor of Anatomy, Government Medical College & Hospital, Aurnagabad 431005

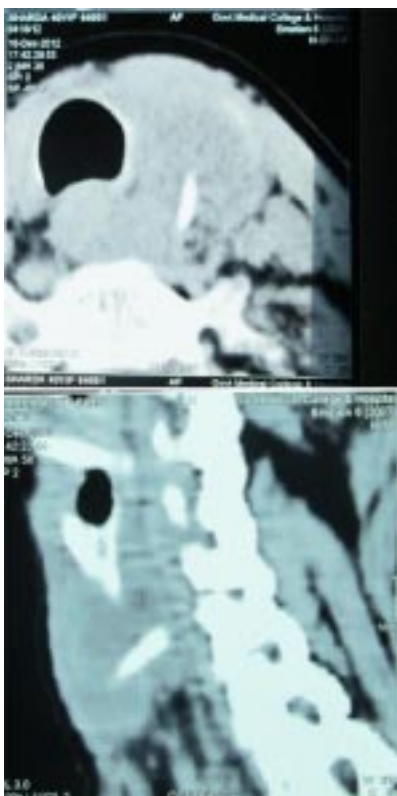


Fig 2 — Preoperative CT Neck Images, showing FB of Axial Image (Top) and Sagittal Image (Bottom)

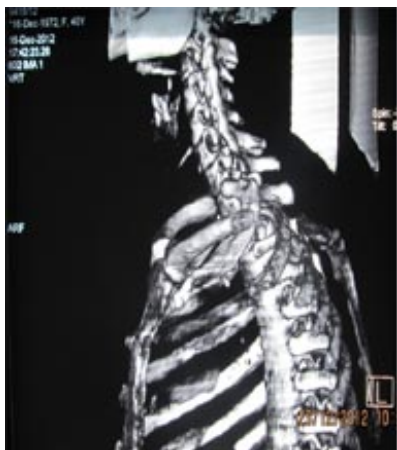

Fig 3 — Reconstructed image – sagittal : showing FB in front of T1 Vertebra

oesophagus, mediastinitis, or vascular complications all of which can morbidity or even cause death. The mechanism of perforation is thought to be a combination of local inflammation of oesophageal wall and direct pressure necrosis.

• The rarity of an esophageal foreign body migrating to the thyroid gland may be attributed to the fact that each thyroid lobe is attached to the trachea by a dense consolidation of connective tissue, called Berry's ligament. X-ray is not conclusive in most such cases so we can't visualize the F.B. in first instance. Ultra-

- A horizontal collar incision taken over anterior neck midway between upper border of thyroid and supra-sternal notch.
- Strap muscles separated by blunt dissection.
- Thyroid gland visualised.
- Left lobe found to be enlarged swollen and haemorrhagic.
- Foreign body was palpated inside left lobe of thyroid, which
- Was explored and removed completely.
- Incision closed and dressing done. procedure uneventful (Figs 4&5).

**DISCUSSION**

Ingestion of a fish bone is a common otolaryngological emergency. This occurs frequently in Asian populations, where it is common to eat fish that has not been deboned. Although fish bones will spontaneously pass through the digestive tract, most fish bones are impacted at the tonsils or base of the tongue and can be removed easily with minimal morbidity. Fish bones retained in the oesophagus can result in complications such as retropharyngeal abscess, perforation of

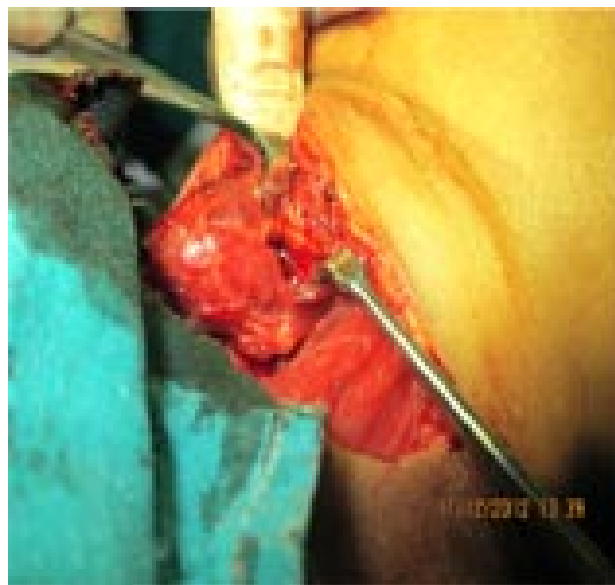

Fig 4 — Showing intraoperative photograph of left thyroid lobe explored



Fig 5 — Approximately 2 x 0.25 cms fish bone is retrieved

sonography and a CT scan of the neck are considered the most helpful diagnostic tools to determine the size, type, location and orientation of a migrated fish bone and its relationship to the other structures of the neck. Exploration for a migrated F.B. from oesophagus in thyroid gland is a challenging task. Here in our case fish bone was removed after careful splitting of thyroid lobe without doing lobectomy.

- Exploration for a migrated esophageal foreign body in the thyroid gland is a challenging task.
- Fish bones was identified and removed after careful splitting of the thyroid lobes, without the need for thyroid lobectomy, because the damaged thyroid lobes was easily repaired with vicryl and drain left postoperatively.

**CONCLUSION**

• One must be aware of the changing nature of the patient's complaints. A case involving an enlarging thyroid mass and a history of foreign body ingestion should alert the physician to the possibility of a penetrating, migrating foreign body in the thyroid gland, with subsequent infection and inflammation. Ultrasonography and CT scan should be performed to investigate if in doubt and surgical removal of FB in thyroid gland can be achieved with minimal tissue ablation.