

Case Report

Asymptomatic translocated intrauterine contraceptive device in urinary bladder — an unusual presentation

Anitha Vijay¹, Deepa Shanmugham², Thirupurasundari Rangaswamy³

Perforation of urinary bladder by an Intra uterine contraceptive device remaining asymptomatic is a rare entity. We present a case of 26 year old female (Para 2 Live 2) with a history of expulsion of foreign body during micturition, without any urinary disturbances. She gave a history of copper T Intra uterine contraceptive device insertion 3 years ago, in her puerperal period which was assumed to have expelled spontaneously later on. On evaluation with x-ray and ultrasound pelvis, a diagnosis of displaced copper T in urinary bladder was made. It was confirmed by cystoscopy and was removed in the same sitting.

[J Indian Med Assoc 2019; 117: 26-7]

Key words : Intra uterine contraceptive device, urinary bladder.

Intrauterine contraceptive device (IUCD) is the most widely used method of reversible contraception¹. IUCD has been used as an effective, safe and economic method of contraception with low rates of complications. The complications that are commonly reported include dysmenorrhoea, menorrhagia, pelvic infection, pregnancy and uterine perforation². Migration of copper T IUCD into adjacent organs is very uncommon. Till now around 70 cases of migration to urinary bladder have been reported in scientific literature, half of them resulting in stone formation, remaining with inflammatory reaction ranging from erythema to peri vesical inflammatory mass³. Migrated copper T in urinary bladder remaining asymptomatic without any secondary complications as in this case is not yet reported.

CASE REPORT

A 26 year female (Para2Live2Abortion1) presented to our gynecology outpatient department with a history of expulsion of a foreign body during micturition. She had no history of dysuria, hematuria or any other urinary disturbances. She gave negative history for vaginal discharge and menstrual abnormalities. She had no history of fever or pain lower abdomen. There was a history of insertion of copper T intrauterine contraceptive device 3 years ago, 4 weeks after her second delivery. Patient conceived 1 year after the insertion of copper T, for which she underwent ultrasound pelvis and was told that there was an intrauterine gestation of 6 weeks with absent IUCD. Assuming spontaneous expulsion, she underwent medical termination of pregnancy with concurrent laparoscopic sterilization elsewhere. Patient has remained asymptomatic thereafter.

Examinations — On bimanual pelvic examination by us, cop-

per T thread was not felt. Uterine sounding did not reveal the presence of copper T inside the uterine cavity.

Investigations — X-ray pelvis with uterine sound showed a copper T device slightly to the right of midline, away from the uterine sound (Fig 1). Her ultrasound pelvis revealed an echogenic linear structure in the lumen of the urinary bladder in contact with the base of the bladder (Fig 2). No mass, calculus or blood clots were seen in the lumen of urinary bladder. A sonological diagnosis of displaced copper T in bladder was given.

Cystoscopy showed the stem of copper T in the lumen of the bladder without any surrounding inflammatory reaction (Fig 3). Bladder wall was intact. There was no calculus or inflammatory mass. Ureteral orifices were normal. In the same sitting the copper T was removed through the cystoscope.

On gross examination of the removed copper T IUCD, a portion of the vertical stem was missing correlating with the history of expulsion of foreign body by the patient. Patient had an uneventful post-procedure period.

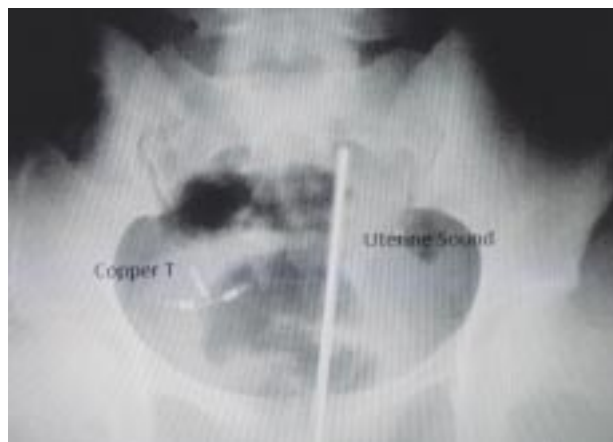


Fig 1 — X- Ray Pelvis with uterine sound demonstrates a copper T IUCD to the right of the midline, away from the uterine sound

Department of Obstetrics & Gynaecology, Aarupadai Veedu Medical College & Hospital, Kirumampakkam, Pudukcherry 607402

¹MD (Obstet & Gynaecol), Assistant Professor and Corresponding author

²MD (Obstet & Gynaecol), Assistant Professor

³MD, DGO, Professor

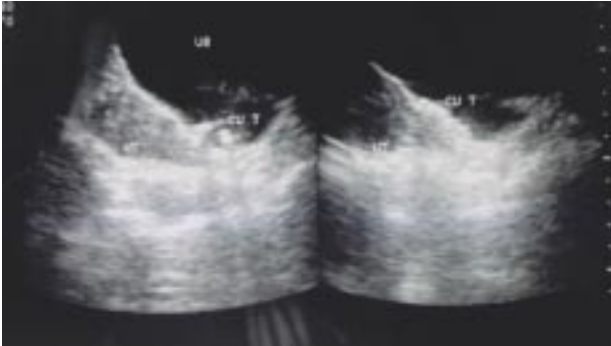


Fig 2 — Ultrasound pelvis revealed an echogenic linear structure in the lumen of the urinary bladder in contact with the base of the bladder. UB – Urinary Bladder, UT – Uterus, Cu T – Copper T IUCD

DISCUSSION

IUCD is the most popular method of reversible contraception due to its high efficacy for fertility regulation, low risk and low cost, especially in the developing countries. However, use of IUCD has been associated with some adverse effects like abnormal uterine bleeding, pelvic inflammatory disease, uterine perforation and migration to adjacent organs². Although devices may migrate spontaneously into and through the uterine wall, most perforations occur or at least begin at the time of insertion. This risk increases particularly during the puerperium when the uterine wall is thin and fragile⁴.

Secondary perforation can occur by slow migration through the muscular wall of the uterus which can be augmented by spontaneous uterine contractions or bladder contractions⁵.

An IUCD in the bladder can also be the consequence of inserting it erroneously in the bladder through the urethra⁶. In our case, the cystoscopic finding of absent mucosal lesions in the presence of IUCD may be consistent either with an early bladder perforation during insertion of the device or an erroneous placement of the IUCD directly in the bladder by an inexperienced para medic lacking basic anatomical knowledge.

Few articles have been reported regarding migration of copper T IUCD with secondary complications. These patients presented with abdominal or pelvic pain and lower urinary tract symptoms like frequency, hematuria, dysuria, retention of urine secondary to lithiasis. Persistent or recurrent urinary tract infections not responding to antibiotic therapy is the most frequent presentation in them.

The migrated IUCD may remain silent for a long period and not be discovered until it is found to be missing. In a case series, nine out of ten patients were noted to have lost their IUCD years before the development of urinary tract symptomatology and instead of carrying out radiological investigations, they were told that the IUCD must have fallen out⁴.

Thorough investigations must be performed in all cases of missing IUCD. Pelvic radiography will reveal the presence of IUCD within the patient, as it is radio opaque. Various investigative tools like Ultrasound, CT scan can be used to locate the IUCD.

All the IUCD in the bladder must be removed, whether they are

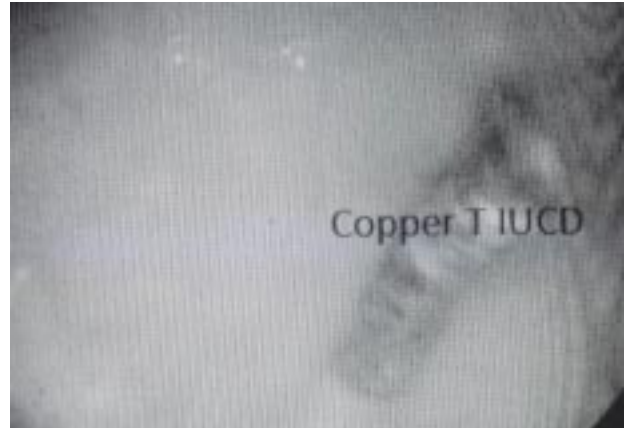

Fig 3 — Cystoscopy showed the stem of copper T in the lumen of the urinary bladder without any surrounding inflammatory reaction

symptomatic or not, in view of future complications. When there is a suspicion of IUCD in the bladder, cystoscopy is the best option through which both confirmation of diagnosis and retrieval is possible in the same sitting^{7,8}.

With this case note, we would like to emphasize that any patient undergone copper T insertion should have a regular follow-up, even though asymptomatic and it should never be assumed that the device has expelled unless it is seen.

REFERENCES

- 1 Chandra A, Martinus GM, Mosher WD — Fertility, Family planning and Reproductive healths of US women: Data from the 2002 National Survey of Family growth. National Centre for health Statistics. *Vital Health Stat* 2005; 23: 1.
- 2 Hatcher RA, Trussell J, Nelson AL — Contraceptive technology, 19th Ed. New York, Ardent Media, 2007.
- 3 Istanbuluoglu MO, Ozcimen EE, Ozturk B, Uckuyu A, Cicek T, Gonen M — Bladder perforation related to intrauterine device. *J Clin Med Assoc* 2008; 71: 207-9.
- 4 Sallami Sataa, Ben Rhouma Sami, Rebai Sabeur, Cherif Karim, Horchani Ali — Bladder Calculus Resulting from the Migration of an Intrauterine Contraceptive Device: A Report of Ten Cases. *Int J Nephrol Urol* 2011; 3: 54-61.
- 5 Singh I — Intravesical Cu-T emigration: an atypical and infrequent cause of vesical calculus. *Int J Urol Nephrol* 2007; 39: 457-9.
- 6 McNamara M, Kennan N, Buckley AR — Copper-7 perforation of the uterus and urinary bladder with calculus formation-sonographic demonstration. *Br J Radiol* 1985; 58: 558-9.
- 7 Rafique M, Rauf A, Khan NA, Haque TU — An unusual cause of vesical stone: a migrant intrauterine device. *Eur J Contracept Reprod Health Care* 2003; 8: 170-2.
- 8 Kassab B, Audra P — The migrating intrauterine device. Case report and review of the literature. *Contracept Fertil Sex* 1999; 27: 696-700.