

## Case Report

# Bilateral 3rd, 4th, 5th and 6th cranial nerve palsy : consequence to cervical injury

Rajesh S Joshi<sup>1</sup>

We report a 19-year-old male presented to ophthalmology out patient department with acute onset painless bilateral 3rd, 4th, 5th & 6th cranial nerve palsy after an injury to the back of neck because of fall from the bicycle. He was unhurt otherwise. He had no head injury. Patient had a weakness in both upper and lower limbs but the rest neurological examination was normal. On MRI of spine he had a swelling of spinal cord with obliteration of anterior and posterior subarachnoid space noted from C3-C5 level. There was no evidence of atlanto-axial dislocation or tonsillar herniation noted. His CT-scan of brain was normal. The type of injury and the presentation of the patient were unexplained to us. He showed improvement after the treatment with intravenous 1 gram methyl prednisolone in a normal saline daily for 3 days. Involvement of oculomotor nerves should be considered in the setting of cervical injury.

[J Indian Med Assoc 2019; 117: 32-3]

**Key words :** Cervical injury, third, fourth, sixth & fifth nerve palsy.

**B**ilateral involvement of oculomotor, abducens, trochlear & trigeminal nerve after an injury to the cervical spine without trauma to the brain is a rare condition. This may be the first such case report, as no similar case was found in our review of English literature. Mechanism of injury in this case is difficult to determine. Rapid improvement in the ocular movements suggests few mechanisms which are relevant to this case.

### CASE REPORT

A 19 years old male presented to the out patient department of ophthalmology with complaint of drooping of both lids. He gave history of fall from his bicycle, leading to injury to the back of his neck. He was otherwise unhurt. He had a weakness in both upper & lower limbs. He did not lose consciousness & there was no history of diplopia, convulsions, vomiting & bleeding from nose & ear. He did not have bowel and bladder problem.

On general examination patient was conscious, oriented & his all higher centre functions were normal. There was anesthesia on the forehead, cheek, lower eyelid, and mandible.

On ocular examination his visual acuity was 20/20 in both the eyes. He had bilateral moderate ptosis with dilated pupils not reacting to light (Fig 1). Corneal sensations were reduced in both the eyes. His eyes were parallel in primary position; however his ocular movements were restricted in all directions. Fundus examination was normal.

Patient was referred to the Orthopedic Department for further evaluation of cervical injury. Patient had a weakness in both upper and lower limbs. Power in both the limbs was grade II. Patient was given cervical collar. He was started on systemic steroids.

MRI study of cervical spine was advised to rule out cervical injury. MRI showed normal curvature & alignment. There was subtle swelling of spinal cord with obliteration of anterior and posterior

subarachnoid space noted from C3-C5 level (Fig 2). The cranio vertebral junction was normal & there was no evidence of atlanto-axial dislocation or tonsillar herniation noted.

In view of multiple cranial nerve palsies & suspicion of head injury CT scan of head was advised which was normal.

Patient was started on intravenous methyl prednisolone 1 gram daily for consecutive 3 days. Patient started improving from the neurological deficit from the third day (Fig 3 & 4).




Fig 1 — Bilateral moderate ptosis

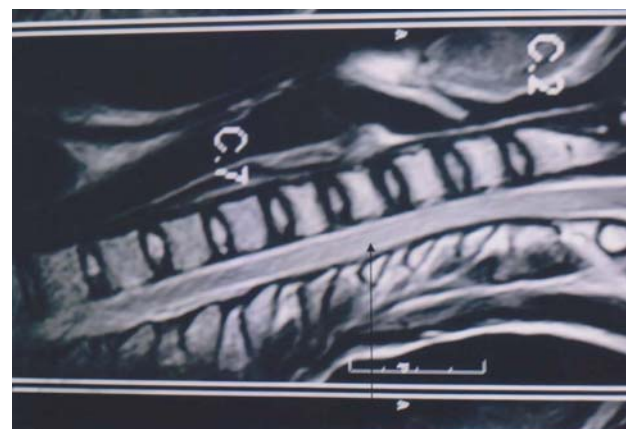


Fig 2 — MRI showing swelling of spinal cord

Department of Ophthalmology, Vasantrao Naik Medical College, Yavatmal 445001

<sup>1</sup>MS, DNB (Ophthalm), Associate Professor and Corresponding author

### DISCUSSION

Lesions affecting the oculomotor, trochlear, abducens & fifth nerve may be located anywhere from the nuclei to the termination of the nerves in the extra-ocular muscles in the orbit. They may present to the clinician as isolated partial or complete nerve palsy with or without neurological or systemic involvement. The ophthalmic and oculomotor complications



Fig 3 — showing improvement in ptosis

of cervical injury are largely unknown. Commonly impaired functions include ocular accommodation, convergence, and stereo acuity seems to be caused by brain stem lesion<sup>1</sup>.

This case was of interest since the patient presented to the ophthalmic out patient department first and bilateral oculomotor, abducens, trochlear & trigeminal nerve involvement in the setting of cervical trauma without head injury is not yet been documented.

Bilateral involvement of multiple ocular cranial nerve palsies in the settings of out patient is rare<sup>2</sup>. Irregular involvement of cranial nerves does occur, like bilateral sixth nerve involvement along with involvement of left third nerve<sup>3</sup>. Head injury as a cause of isolated third, fourth, sixth nerve palsy is reported in the literature<sup>4,5</sup>.

Bilateral involvement of sixth nerve does occur after cervical trauma<sup>4,6</sup>. It may be seen either with extension or flexion injury of neck. Affection of the sixth nerve in the flexion injury is rare<sup>6</sup>. In patients with bilateral ophthalmoplegia, several possibilities must be considered. When the etiology is neurogenic, the lesion may be anywhere from the brainstem to the orbit. Extrinsic masses adjacent to the brainstem, especially those grow along the skull base and lesions in and around the cavernous sinus, such as meningiomas and pituitary adenoma, are particularly prone to produce both unilateral and bilateral ocular motor neuropathies<sup>7</sup>. Pathologic processes like inflammation, ischemia, hemorrhage in acute cases may be responsible. In most cases, the clinical history and a careful clinical examination, when combined with appropriate neuroimaging are sufficient to identify the site and nature of the disease process.

Direct injury to the third nerve leading to its palsy is a rare event<sup>5</sup>. Tiffin *et al* performed a retrospective study of acquired third, fourth & sixth cranial nerve palsies of a varying etiologies that were seen in the Orthoptic Department at Nine-wells Hospital, UK. They found no case of isolated third nerve palsy attributable to direct trauma<sup>2</sup>. On the contrary fourth nerve palsy can occur after apparently trivial head trauma probably because of its long intracranial course & a very slender connection to the brain stem.

Involvement of the fourth & sixth cranial nerve after spinal traction for stabilization of a damaged or abnormal spine have been reported in the literature<sup>8</sup>. It occurred because of atlantoaxial subluxation. However no atlantoaxial dislocation was observed in



Fig 4 — showing improvement of the ocular movement

our case on MRI study of cervical spine.

The exact mechanism of involvement of the bilateral multiple cranial nerve palsies in this patient is unknown. Rapid neurological recovery, both from cranial nerve & sensory deficit suggest some form of brain stem ischemia due to vertebral artery spasm or its compression because of edema, as patient responded to steroids. Another reason could be differential movement between the base of the skull & the upper part of the cervical spine at the time of injury.

This case is being reported to consider cervical spine injury as a cause for oculomotor nerve palsies without the involvement of brain.

### REFERENCES

- 1 Treleven J, Jull G, Low Choy N — The relationship of cervical joint position error to balance and eye movement disturbances in persistent whiplash. *Man Ther* 2006; **11**: 99-106.
- 2 Tiffin PA, MacEwen CJ, Craig EA, Clayton G — Acquired palsy of the oculomotor, trochlear and abducens nerves. *Eye (Lond)* 1996; **10**: 377-84.
- 3 Ruiz-de-río N, Arbizu-duralde A, Miranda-lloret P, Asencio-durán M, Peralta-calvo J — Bilateral sixth nerve and left third nerve palsy after head trauma parálisis del vi par bilateral y iii par izquierdo postraumático. *Arch Soc Esp Oftalmol* 2006; **81**: 41-4.
- 4 Advani RM, Baumann MR — Bilateral sixth nerve palsy after head trauma. *Ann Emerg Med* 2003; **41**: 27-31.
- 5 Muthu P, Pritty P — Mild head injury with isolated third nerve palsy. *Emerg Med J* 2001; **18**: 310-11.
- 6 Uzan M, Hanci M, Sarioglu AC, Kaynar MY, Bozkus H — Bilateral traumatic abducens nerve paralysis with cervical spine flexion injury. *Eur Spine J* 1996; **5**: 275-77.
- 7 Agarwal P, Sharma K, Gupta RK, Dutta NR, Kumar S, Gujral RB — Acute bilateral ophthalmoplegia secondary to metastatic prostatic carcinoma. *J neuroophthalmol* 1995; **15**: 45-47
- 8 Pinches E, Thompson D, Noordeen H, Liasis A, Nischal KK — Fourth and sixth cranial nerve injury after halo traction in children: a report of two cases. *J AAPOS*. 2004; **8**: 580-5.