

Case Report

Oculo-auricular-fronto-nasal syndrome – a new entity

Sujata Chahande¹, Ramesh Murthy²

We describe a unique combination of fronto nasal malformations and oculo auricular vertebral syndrome without any vertebral defects and with bilateral involvement of eyes. The oculo auricular vertebral syndrome manifests with defects of the first and second branchial arches including hemifacial microsomias and Goldenhar's syndrome. We describe the clinical features in a 6-year-old male child with lid colobomas, ocular dermoids and dermolipomas, hearing defects, zygomatic hypoplasia but with bilateral involvement and absence of heart disease, absence of encephalocele and without any maxillary or mandibular hypoplasia. We name this unique entity as Oculo-auricular-fronto-nasal syndrome.

[J Indian Med Assoc 2019; 117: 35-6]

Key words : Corneal dermoid, lipodermoid, preauricular skin tags, lid coloboma, zygomatic.

Fronto-nasal malformations (FNM) is a developmental field defect representing abnormal morphogenesis of the fronto-nasal eminence while oculo-auricular-vertebral spectrum (OAVS) describes a more broader range of the first and the second branchial arch defects including hemifacial microsomias and Goldenhar's syndrome¹. We describe a 6 year old boy with a rare combination of features of fronto-nasal malformations (FNM) and oculo-auricular vertebral syndrome(OAVS) without any vertebral defects and with a bilateral involvement. The uncommon features in our patient was the absence of heart disease, absence of encephalocele, bilateral involvement, no maxilla or mandibular involvement with the presence of zygomatic hypoplasia.

CASE REPORT

A 6 year old male patient born of non- consanguineous marriage presented with congenital deformities of upper eyelids, preauricular skin tags and ocular dermoids. There was no positive family history of similar eye anomalies.

Examinations — Patient had vision of finger counting more than 3m in each eye. There was bilateral total complete upper lid coloboma which was quadrangular involving medial third of upper eyelid and about one third eye lid width (Fig 1). Patient had broad dorsum of nose and hypertelorism along with telecanthus. The conjunctiva showed presence of a lipodermoid temporally in the right eye lateral fornix along with a limbal dermoid located at the inferior limbus from 5 to 7 o'clock which was confluent with the lipodermoid. In the left eye there was a limbal epithelial dermoid at the inferior limbus from 4 to 8 o'clock encroaching on the cornea upto the mid pupillary zone. There was no sign of exposure keratitis. The pupils were briskly reacting to light. Patient's intraocular pressures were found to be normal. Fundus examination revealed the presence of tilted optic disc in both eyes. The ocular motility was normal.

Patient had multiple pre auricular skin tags, four on the right

side and two on the left with no external ear deformity (Fig 2). Patient had left hemi-facial microsomia with misaligned teeth along with cleft palate. There was decreased hearing due to conductive deafness. The upper and lower jaws were normal but with zygomatic hypoplasia. The patient had delayed milestones.

X-Ray of the skull confirmed the presence of bilateral zygomatic hypoplasia with normal maxillary and mandibular bones. X Ray spine did not show any vertebral anomaly. Computer aided tomography of brain was normal.

DISCUSSION

The minimum clinical features for the diagnostic confirmation of Goldenhar's syndrome is the presence of unilateral ear involvement (microtia) together with preauricular tags². Ocular abnormalities associated with Goldenhar's syndrome include microphthalmia, anophthalmos, epibulbar dermoid and lipodermoid and strabismus³. Bilateral ocular involvement which was present in our patient, is rare 10%⁴.




Fig 1 — Face photograph of a 6 year old boy with bilateral total complete upper lid coloboma, broad dorsum of nose and hypertelorism along with telecanthus, lipodermoid temporally in the right eye lateral fornix along with a limbal dermoid located at the inferior limbus & a limbal epithelial dermoid at the inferior limbus in the left eye & 2 preauricular skin tags on left side

Department of Ophthalmology, BJ Government Medical College & Sassoon General Hospital, Pune 411001

¹MS, DOMS, Associate Professor and Corresponding author

²FRCs, Medical Director, Pediatric Ophthalmology, Strabismus and Oculoplasty, Axis Eye Clinic, Pune 411038

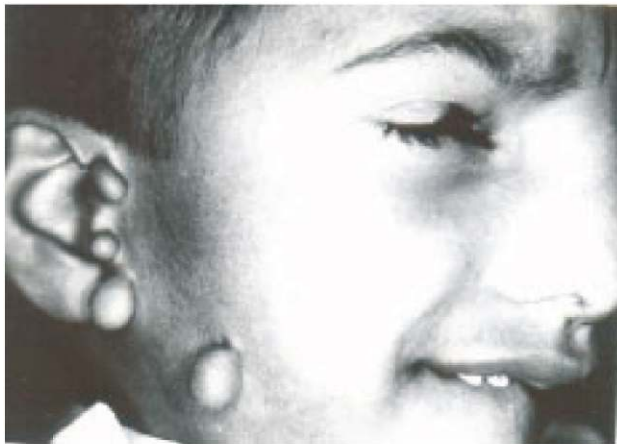

Fig 2 — Face photograph of a 6 year old boy right lateral view with multiple pre auricular skin tags, four on the right side with no external ear deformity with misaligned teeth along with cleft palate and with no corneal exposure on eyelid closure

The NORD studies suggest that in individuals with this disorder, craniofacial malformations resulting in facial asymmetry (hemifacial microsomia) is progressive and initially affects bone and soft tissue of lower jaw (mandibular hypoplasia). As the disease process progresses, asymmetry of the lower jaw becomes more pronounced and causes associated malformations of upper jaw (maxilla), nose and orbit. Our patient was unique as he had no maxilla or mandibular involvement but had zygomatic hypoplasia. Zygomatic hypoplasia has classically been described as a feature of Treacher-Collins Syndrome. In addition the child had conductive hearing loss and cleft palate which is common to both Goldenhar's syndrome and Treacher-Collins syndrome^{2,5}.

The absence of vertebral involvement is another unique feature of this case. The incidence of vertebral involvement in Goldenhar's Syndrome is reported to be as high as 40%⁶. However some studies mention that there was no absolute correlation between the presence of any of the formative or segmentation vertebral defects and that of other concomitant malformations and thus patients with various groupings of Goldenhar related anomalies should be considered a single entity to which Goldenhar's association could be applied⁷.

CONCLUSION

To conclude, though the present case does not have all the features typical of Goldenhar's Syndrome or Treacher-Collins Syndrome, it is unique in the presentation of bilateral involvement, zygomatic hypoplasia without vertebral and spinal involvement. We would therefore describe it as Goldenhar's Syndrome having a unique syndrome pattern or a distinct entity. We would like to label this entity as 'Oculo-Auriculo-Fronto-Nasal Syndrome'.

REFERENCES

- 1 Ignacio Rodríguez J, Palacios J, Lapunzina P — Severe axial anomalies in the oculo-auriculo-vertebral (Goldenhar) complex. *Am J Med Genet* 1993; **47**: 69-74.
- 2 The National Organization for Rare Disorders, Inc, Report Goldenhar Syndrome [Oculo auricular Vertebral Spectrum] Disease Information, 1987, 1989, 1994, 1997, 1998. Email Webmaster (updated April 24 2001)
- 3 Kaye CI, Martin AO, Rollnick BR, Nagatoshi K, Israel J — Humanoff M, *et al* — Oculoauriculovertebral Nomalies : segregation Analysis. *Am J Med Genet* 1992; **43**: 913-17.
- 4 Sharma JK, Pippal SK, Raghuwanshi SK, Shitij A — Goldenhar – Gorlin's syndrome ; A case report . *Indian J Otolaryngol Head*

Neck Surgery 2006; **58**: 97-101.

- 5 Marres HA, Cremers CW, Dixon MJ, Huygen PL, Joosten FB — The Treacher Collins syndrome. A clinical, radiological, and genetic linkage study on two pedigrees. *Arch Otolaryngol Head Neck Surg* 1995; **121**: 509-14.
- 6 Kulkarni VV, Shah MD, Parikh AA — Goldenhar syndrome : A Case report. *J Postgrad Med* 1985; **31**: 177-9.
- 7 Gibson J N, Sillence DO, Taylor TK — Abnormalities of the spine in Goldenhar Syndrome. *J pediatric orthopedics* 1996; **16**: 344-9.
- 8 Medscape Reference -Manifestation of craniofacial syndrome, Ted L, Tewfik, MD Arlen D Meyers MD, Updated, May 20, 2011. emedicine.medscape.com/article/844209.
- 9 Mehta B, Nayak C, Sawant S, Amladi S — Goldenhar syndrome with unusual features. *Indian J Dermatol Venereal Leprol* 2008; **74**: 254-6.
- 10 Das A, Majumdar S, Chatterjee SS — Atypical case of oculo-facio-auriculo-vertebral dysplasia (goldenhar-gorlin syndrome). *Indian J Ophthal* 1999; **47**: 131-3.

If you want to send your queries and receive the response on any subject from JIMA, please use the E-mail facility.

Know Your JIMA

Website	: www.ejima.in
For Editorial	: jima1930@rediffmail.com
For Circulation	: jimacir@gmail.com
For Marketing	: jimamkt@gmail.com
For Accounts	: journalaccts@gmail.com

HOSPITAL TENDER NOTICE

A 130 years old reputed charity organisation "Brahman Sabha, Mumbai", which besides offering educational / cultural services, offers excellent medical facilities through its maternity hospital & nursing home with associated testing facilities in South Mumbai area.

BRAHMAN SABHA DESIRES TO OUTSOURCE VARIOUS DIAGNOSTIC & TESTING FACILITIES FOR ITS HOSPITAL ESTABLISHMENT & hence wishes to invite offers through tender process.

Parties interested in running our hospital & / or Nursing Home on outsourcing basis may also send their Expression of Interest by mail on sheveddileep@gmail.com or letter.

Interested parties should collect tender papers from office between 10 am & 6 pm from the following address:

Brahman Sabha, Mumbai
190, Raja Rammohan Roy Marg, Mumbai 400 004
Mr. Suresh Agvekar
Tel: 23864825 / 4625 Mob: 9167461165

For site visit, please contact
Mr. Sushil Bapat, Tel: 98212 99989