

## Case Report

# A rare case of vaginal dermoid cyst

Urvashi Barman Singh<sup>1</sup>

**Vaginal dermoid cyst is a rare condition. Ultrasound is the investigative tool for this condition which may be treated surgically through a transvaginal approach. We report a case of vaginal dermoid cyst.**

[J Indian Med Assoc 2019; 117: 33-4]

**Key words :** Vaginal dermoid cyst.

The finding of paravaginal dermoid cyst is rare in gynecology practice. The key in the management is the preoperative assessment using transvaginal ultrasound, and the appropriate surgical intervention. We report a case of vaginal dermoid cyst and the surgical procedure in its management.

### CASE REPORT

A 30 year-old non-pregnant P 3+1 with previous vaginal deliveries woman presented to us with complaints of something coming out of vagina since 1 year. On performing a gynecological exam. a vaginal cyst 3 X 2 inches was seen in the posterior wall.

An ultrasound was requested which showed a non-vascular mass measuring 8.4 cm. by 7.5 cm by 6.1 cm, with low level echogenic material as well as echogenic bands, situated within the posterior wall of the vagina, in the rectovaginal space; the rest of the pelvis was normal; with an impression of a dermoid cyst.

She was sexually active with history of dyspareunia for last 1 year, prior to that she was sexually active without any problems. The remainder of her history was non-contributory.

Under general anesthesia this cyst was removed. Incision was made on the vaginal mucosa on top of the mass extended toward the cervix, measuring approximately 6 cm. The mass surface was identified, blunt dissection was carried out (Figs 1&2), the mass ruptured revealing a sebaceous material which was extruded and collected in a bowl. The cyst wall was then dissected free from the rectovaginal space with good homeostasis. Incision was sutured with a running locked 0 Vicryl suture, and a vaginal pack was inserted.

The patient was discharged the next day after removing the vaginal pack in good condition. Histopathological examination of the cyst wall, showed keratinized stratified squamous epithelium. Subepithelium show fibrocollagenous tissue and lymphomononuclear cell infiltrate. There were few sebaceous and apocrine glands noted. The findings were consistent with a diagnosis of a dermoid cyst.

### DISCUSSION

Vaginal cysts are classified microscopically, according to their epithelial lining, as: Mullerian, epidermal inclusion, Gartner's duct remnants (mesonephric), Bartholin's duct, endometriotic and other rare types<sup>1</sup>, including dermoid cyst, ectopic ureterocele, paraurethral cyst and unilateral hematocolpos.

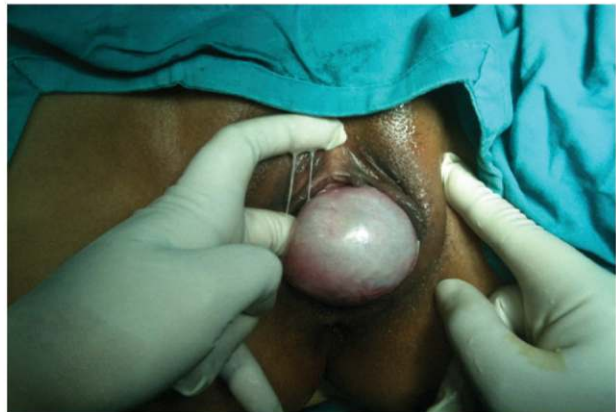

Fig 1 — Vaginal wall cyst of 3x2 inches seen in posterior wall

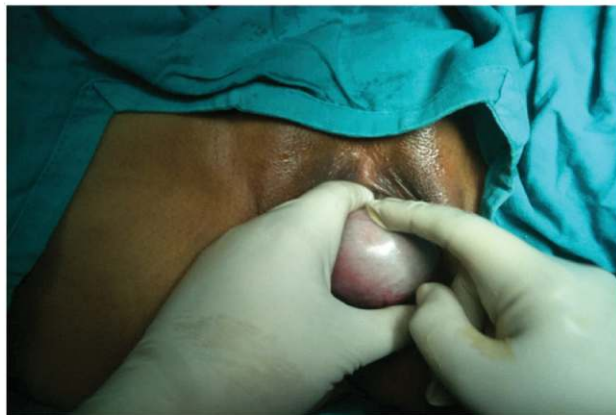

Fig 2 — Postvaginal wall cyst during surgery

A dermoid cyst (Benign cystic teratoma) is a benign germ cell tumor that contains well-differentiated derivatives of all three germ cell layers.

Ovaries are the commonest site for this tumor, where it is the commonest neoplastic tumor in children and adolescent accounting for more than half of ovarian neoplasms in women younger than 20 years of age. More than 80% of ovarian benign dermoid cysts occur during reproductive years.

A dermoid cyst has also been reported from other parts of the human body other than the ovaries, with rare occurrence. It can be anywhere in the gastrointestinal tract from the floor of the mouth to the colon<sup>2,3</sup>.

Department of Obstetrics & Gynaecology, MLN Medical College, Allahabad 211001

<sup>1</sup>MS, Assistant Professor and Corresponding author

Dermoid cysts have also been reported in male patients, in different parts of their body<sup>6</sup>.

Vaginal dermoid is a rare condition. Only five cases have been reported in English literature. First observed in 1899 by Stokes<sup>9</sup>, who reported a 44 year old woman who had a 1 centimeter cyst removed from just within the hymen. The cystic contents showed neumerousseba-ceous glands and a few hair follicles. Curtis<sup>1</sup> described an ulcerated orange-sized necrotic cyst, containing hair and sebaceous materials in the vaginal mucosa. Johnston<sup>3</sup> described a 4-inch cyst that passed from the vagina in a woman following delivery of her second child. The cyst was filled with thick sebaceous material with matted hair and had been attached to the vaginal wall by a narrow stalk. Hirose *et al*<sup>4</sup> reported another case, having repeated painful right vaginal wall cyst, which was excised and was found to be a dermoid cyst confirmed by histopatological examination.

Preoperative diagnosis of the exact nature of a vaginal cyst can be difficult. SSN SIU *et al*<sup>8</sup> reported the sonographic characteristics of a vaginal cyst, which was consistent with a dermoid cyst and was confirmed by histopathological exam after surgical excision of the cyst. The same sonographic features were found in our case.

Transvaginal excision of this type of cyst appears to be an appropriate surgical treatment option which was inconformity with some of the previous cases<sup>4,8,9</sup>.


#### CONCLUSION


Vaginal dermoid cyst is a rare condition, which can be diagnosed with ultrasound. Transvaginal excision appears to be an appropriate surgical treatment option.


#### REFERENCES

- 1 Curtis AH — Transactions of Societies. Chicago Gynecological Society. *Surg Gynecol Obstet* 1913; **16**: 715.
- 2 Fernandez-Cebrian JM, Carda P, Morales V, Galindo J— Dermoid cyst of the pancreas: a rare cystic neoplasm. *Hepatogastroenterology* 1998; **45**: 1874-6.
- 3 Fujita K, Akiyama N, Ishizaki M, Tanaka S, Ohsawa K, Sugiyama H, *et al*— Dermoid cyst of the colon. *Dig Surg* 2001; **18**: 335-7.
- 4 Hirose R, Imai A, Kondo H, Itoh K, Tamaya T — A dermoid cyst of the paravaginal space. *Arch Gynecol Obstet* 1991; **249**: 39-41.
- 5 Johnston HW — A dermoid cyst of the vagina complicated by pregnancy. *Can Med Assoc J* 1939; **41**: 386.
- 6 Longo F, Maremonti P, Mangone GM, De Maria G, Califano L — Midline (dermoid) cysts of the floor of the mouth: report of 16 cases and review of surgical techniques. *Plast Reconstr Surg* 2003; **112**: 1560-5.
- 7 Schuetz MJ, 3rd, Elsheikh TM — Dermoid cyst (mature cystic teratoma) of the cecum. Histologic and cytologic features with review of the literature. *Arch Pathol Lab Med* 2002; **126**: 97-9.
- 8 Siu SS, Tam WH, To KF, Yuen PM — Is vaginal dermoid cyst a rare occurrence or a misnomer? A case report and review of the literature. *Ultrasound Obstet Gynecol* 2003; **21**: 404-6.
- 9 Stokes JE — The etiology and structure of true vaginal cysts. *Johns Hopkins Hosp Rep* 1899; **7**: 109-36.

*Friendly  
Affordable  
Dependable*







- ★ Escorted tours from **Kolkata**
- ★ Air Tickets, Visa & Passport Assistance
- ★ Foreign Exchange ★ World Wide Hotel Booking

For details :  
52/1 Rafi Ahmed Kidwai Road,  
Kolkata 700016  
Tel.: 9830444621, (033) 22172111  
Email: vctplsreoshi@gmail.com

