

Case Report

Epidermoid cyst of the spleen — a case report

Tanvi Rao¹, Shubhakar Bhandary², Lancelot Lobo³

Splenic cysts are rare entities. Epidermoid cysts of the spleen constitute 10% of total splenic cysts. These cysts are more common in children and young adults. We report a case of 21 year-old female who presented with left sided dull aching, intermittent abdominal pain and a palpable mass in the left hypochondrium. USG abdomen showed gross splenomegaly with a large cystic lesion in the spleen. CT scan revealed a grossly enlarged spleen with a cystic lesion suggestive of a splenic cyst and mild hepatomegaly. USG guided aspiration of the cyst and pigtail catheter insertion was done. Cystic fluid analysis was suggestive of epidermoid cyst of the spleen. Laparoscopic total splenectomy was done and histopathological evaluation revealed fibrosed cyst wall with stratified squamous lining confirming the diagnosis of epidermoid cyst of spleen. This case report favours total splenectomy based on the size of the cyst for a better post-operative outcome. A definitive diagnosis of epidermoid cyst of the spleen requires histopathological evaluation.

[J Indian Med Assoc 2019; 117: 27-8]

Key words : spleen, cyst, epidermoid.

Splenic cysts are rare. They may be congenital, neoplastic, vascular, inflammatory and post-traumatic in origin. They contribute 30-40% of the total splenic lesions. Congenital splenic cysts are usually asymptomatic and they are rarely seen. They are more often discovered incidentally due to lack of typical clinical presentation. They constitute approximately 10% of total splenic cysts and are encountered more commonly in children and young adults. They are reported to have a good prognosis¹.

We report a case of epidermoid splenic cyst which was managed by laparoscopic splenectomy.

CASE REPORT

A 21-year-old female with no known comorbidities presented with complaints of vague, dull aching, intermittent, left sided abdominal pain of 2 weeks duration. She had no history of vomiting, abdominal distention or trauma. No significant general examination finding was noted. On local examination, a single non tender 12x12 cm mass was palpable in the left hypochondrium, extending up to the umbilicus, firm consistency, smooth surface and the superior border was not palpable.

USG abdomen showed gross splenomegaly with a large cystic lesion in the spleen measuring 17.2X13.1 cm.

CT scan showed (Fig 1) a grossly enlarged spleen with large predominantly inter-polar, near water density cystic lesion measuring 13X12.7X18 cm, suggestive of a splenic cyst with mild hepatomegaly.

An ultrasound guided aspiration of the cyst and pigtail catheter insertion into the cyst was done. The cystic fluid analysis was suggestive of epidermoid cyst of the spleen.

She was taken up for laparoscopic total splenectomy. Intra-operatively, mobilisation of the spleen was time consuming due to

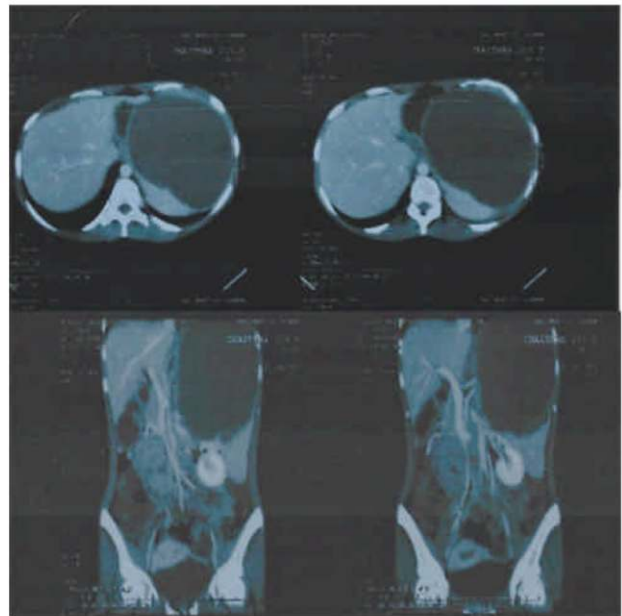


Fig 1 — CT scan showing the cyst in the spleen

dense adhesions to surrounding structures especially at the area of the cyst. Post-operative period was satisfactory and uneventful.

Histopathological report (Fig 2) revealed fragments of spleen with multiple cysts lined by stratified squamous epithelium without adnexa containing laminated keratin. The wall of the cyst showed fibrosis with hyalinisation, confirming the diagnosis of epidermoid cyst of the spleen.

DISCUSSION

Splenic cysts rare and epidermoid cysts of the spleen constitute 10% of splenic cysts. Epidermoid cysts are usually asymptomatic and may present with vague symptoms. Most of these cysts are incidental findings².

Department of General Surgery, KS Hegde Medical Academy (KSHEMA), Mangalore 575018

¹MBBS, Resident, Post Graduate and Corresponding author

²MBBS, DNB (Gen Surg), Professor and Unit Head

³MBBS, MS (Gen Surg), Associate Professor

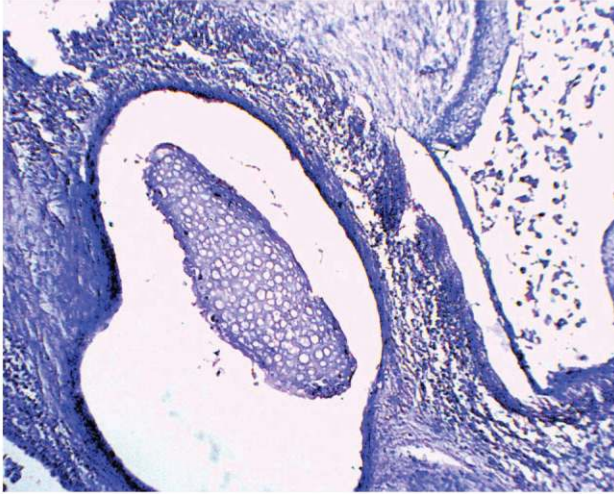


Fig 2 — Histopathological section of the excised cyst (H&E X 100)

Splenic cysts are classified (Fig 3) as Type I cysts (primary or true cysts) with cellular linings and Type II cysts (false or secondary cysts) without cellular linings. Type I cysts may be parasitic or non-parasitic in origin. Non-parasitic cysts may be congenital or neoplastic. Congenital cysts are classified further as epidermoid, dermoid and endodermoid cysts; and neoplastic cysts as hemangiomas and lymphangiomas. Epidermoid cysts are the rarest among all true splenic cysts³.

The origin of true cysts is not very clear. They are said to develop from mesonephric tissue in the developing spleen during early embryonic life. Infolding or entrapment of peritoneal mesothelial cells in the splenic parenchyma during embryogenesis in the intrauterine life is the suggested mechanism of development. The age at presentation ranges from new-born to 50 years, with average age of around 17 years⁴.

It is difficult to differentiate true from false cysts on imaging studies. False cysts tend to have thicker fibrous walls and eggshell like calcifications with internal debris. On USG, epidermoid cysts are well-defined, thin walled, anechoic cystic lesions. Increased echogenicity may be due to intra-cystic haemorrhage, cholesterol crystals and inflammatory necrotic debris (similar to those seen in false cysts). Computerized tomography gives a clearer picture regarding intra-cystic fluid, internal septations or calcifications. The final diagnosis of a splenic cyst always depends on histopathological examination of the cyst wall and not on imaging studies^{4,5}.

Partial splenectomy is a definite solution in treatment of cysts <5cm. Other conservative measures like aspiration and incision and drainage can be tried. Larger cysts of >5cm are best managed by total splenectomy as it prevents serious complications like rupture, haemorrhage, infection and recurrence of cysts. Splenectomy, thus remains a relatively safe procedure when the hilum of the spleen is involved^{4,6}.

In this case, suspecting an infective aetiology, conservative management was attempted with a pigtail catheter to aspirate and drain the cyst. Total laparoscopic splenectomy was decided considering the size of the cyst and positive histopathologic diagnosis of epidermoid cyst of the spleen.

REFERENCES

- 1 Urrutia M, Mergo PJ, Ros LH — Cystic masses of spleen; Radiologic pathologic correlation. *Radiographics* 1996; **16**:

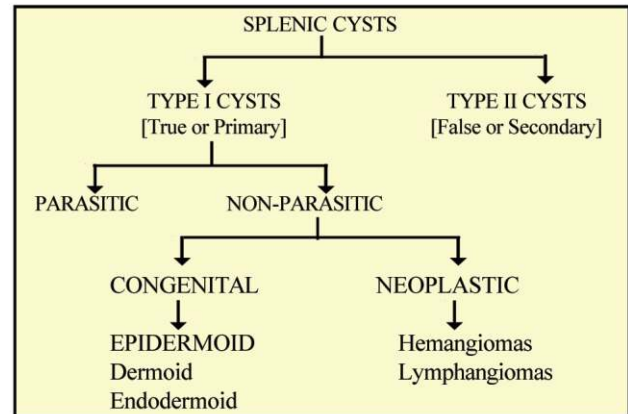


Fig 3 — Classification of splenic cysts

107-29.

- 2 Robbins FG, Yellin AE, Lingua RW, Crsig JR, Turrill FL, Mikkelsen WP — Splenic epidermoid cysts. *Ann Surg* 1978; **187**: 231-35.
- 3 Marjanovic ZO, Djordjevic IM — Epidermoid Splenic Cysts in Children and Adolescents. *Acta Chir Jugosl* 2008; **55**: 63-7.
- 4 Elias AK, Evangelos R, Evangelos C — Surgical management of nonparasitic splenic cysts. *JSLs* 2009; **13**: 207-12.
- 5 Boybeyi O, Karnak I, Tanyel FC, Ciftçi AO, Senocak ME — The Management of Primary Nonparasitic Splenic Cysts. *Turk J Pediatr*. 2010; **52**: 500-4.
- 6 Kalinova K — Giant pseudocyst of the spleen: A case report and review of the literature. *Journal of Indian Association of Pediatric Surgeons* 2005; **10**: 176-78.

Bringing the BEST in Healthcare

400-bed Superspecialty Hospital in Kolkata

MEDICA Superspecialty Hospital
KOLKATA *caring for life*



Our Centres of Excellence

Cardiac Sciences | Neurological Diseases | Orthopaedic Sciences
Kidney Diseases | Breast Diseases | Gastroenterology & GI Surgery
Critical Care | ENT

Medica Helplines

Emergency & Ambulance Help Desk: **033 66520100**

May I Help You: **033 66520154**

Health Check Up: **9230089704**

Corporate Desk: **9230011834**

Physical Therapy & Rehabilitation (Home Services)
Helpline: **7044025087**

Pathology (Home Collection): **9007002626**

Pharmacy Home Service: **8100600100**

For further information, please contact us at:

127 Mukundapur, E M Bypass, Kolkata 700099. ☎ +91 033 66520000

✉ contactus@medicahospitals.in 🌐 www.medicahospitals.in