

## Case Report

# Acute myocarditis due to ingestion of nitrobenzene (paint solvent)

SV Birajdar<sup>1</sup>, Gajanan Halkanche<sup>2</sup>, Virendra B Aswar<sup>3</sup>

A case of acute poisoning with nitrobenzene is presented where clinical evaluation and timely management, with repeated intravenous methylene blue helped to save a life. Acute myocarditis, though not common in cases of nitrobenzene poisoning but presenting solely with this, is very rare. It is important to take care of the secondary cycling of nitrobenzene from body stores in patients presenting late, after heavy exposure.

[J Indian Med Assoc 2019; 117: 29-30 & 32]

**Key words :** Acute methaemoglobinaemia, methylene blue, nitrobenzene poisoning.

Acute poisoning with nitrobenzene causing significant methaemoglobinaemia and acute myocarditis is uncommon but life threatening emergency. Early aggressive management of severe poisoning, strongly suspected on clinical grounds may change the outcome of a patient.

### CASE REPORT

A 30-year-old, conscious and drowsy female presented to Emergency Department of Swami Ramanand Teerth Rural Medical College and Hospital, Ambajogai Dist Beed, Marathwada, Maharashtra with mild cyanosis and a greyish-brown hue, laboured respiration of 26/min, BP 150/90 mm of Hg, pulse rate 90/min, pupils with normal size reacting to light and SpO<sub>2</sub> of 74% on air. Her chest was clear. Immediate BiPAP ventilation with 100% oxygen and improved the SpO<sub>2</sub> to 84% only. There was a history of severe pain in the abdomen, nausea, vomiting, dizziness, chest pain and palpitation. Blood samples drawn for ABG had a chocolate brown colour, which did not improve on exposure to 100% oxygen and showed compensated metabolic acidosis. On ECG heart rate is 90/min, Normal Axis, sinus rhythm with T wave inversion in 3, avL, V2-V6, PR interval 0.12, QTc 0.40, cardiac enzymes is 119.2 and WBC count is 20300, Platelet count 573000 and liver enzymes were slightly raised. Serum creatinine within normal range. A clinical diagnosis of severe acute methaemoglobinaemia with acute myocarditis of unknown origin was made.

### INVESTIGATIONS

**20/01/2013 :** ABG Report-PH-7.42, PCO<sub>2</sub>-35mm of Hg, PO<sub>2</sub>-38 mm of Hg, HCO<sub>3</sub>-22.2, SO<sub>2</sub>-71%.

**20/01/2013 :** Serum Cholinesterase-8963.9, HIV-Non-Reactive.PT-14sec, INR-1.2.

**20/01/2013 :** BUL-20, Serum Creatinine- 0.8, Serum Bilirubin -1.5, SGOT- 36, SGPT-30.

**20/01/2013 :** Serum electrolytes-Na-137, K-3.3, Ca-1.15.

**20/01/2013 :** CPK MB- 119.2,

**22/01/2013 :** Hb-9.3% TLC-20300cu/mm, Platelets-573000cu/mm.

**25/01/2013 :** Reticulocyte Count -1.3%, TLC-15600, Platelets-285000 cu/mm.

**26/01/2013 :** ABG Report-PH-7.44, PCO<sub>2</sub>-40mm of Hg, PO<sub>2</sub>-42mm of Hg, HCO<sub>3</sub>-26.4, SO<sub>2</sub> 74%.

**26/01/2013 :** at 8 am Serum electrolytes-Na-139, K-3.4, Ca-1.12.

**26/01/2013 :** at 5 pm Serum electrolytes-Na-150, K-3.2, Ca-8.07, Mg-2.5.

**26/01/2013 :** BUL-25, Serum Creatinine-0.8.

**24/01/2013 :** CPK MB- 17.5.

**26/01/2013 :** 2DEcho within normal limit,

**27/01/2013 :** CPK MB- 20.

In 100 mg of methylene blue (prepared as 1% sterile solution) and ascorbic acid 500 mg were given IV. This improved her SpO<sub>2</sub> to 92%, which dropped after about three hours, when 50 mg IV methylene blue was repeated and intravenous dexamethasone 6mg 8hrly. Intravenous Vitamin K, 10% dextrose, and an antibiotic were also added. Urine output was maintained above 100 ml/hour with proper hydration and frusemide, maintaining a normal central venous pressure (CVP).

She became stable after six hours with a stable BP of 118/82 and HR of 80/minute. SpO<sub>2</sub> was again 91%. IV methylene blue (50 mg) improved SpO<sub>2</sub> to 97% over the next 15 minutes, only to return to 85% in the next three hours, with a similar response to another dose. Two units of fresh blood were transfused and this improved the SpO<sub>2</sub> to 92-94%. With this waxing and waning picture of symptoms, six hourly gastric lavage with charcoal, purgation with polyethylene glycol (peg leg), intravenous methylene blue every eight hours (three days) and then orally up to seven days, and IV ascorbic acid (500 mg) per day up to six days, was prescribed, till the smell of bitter almonds disappeared completely from the stools.

She improved rapidly after the seventh day with an SpO<sub>2</sub> of 98% on room air. She was discharged on the ninth day on oral iron, folate, ascorbic acid, and liver enzyme supplements and breathing exercises.

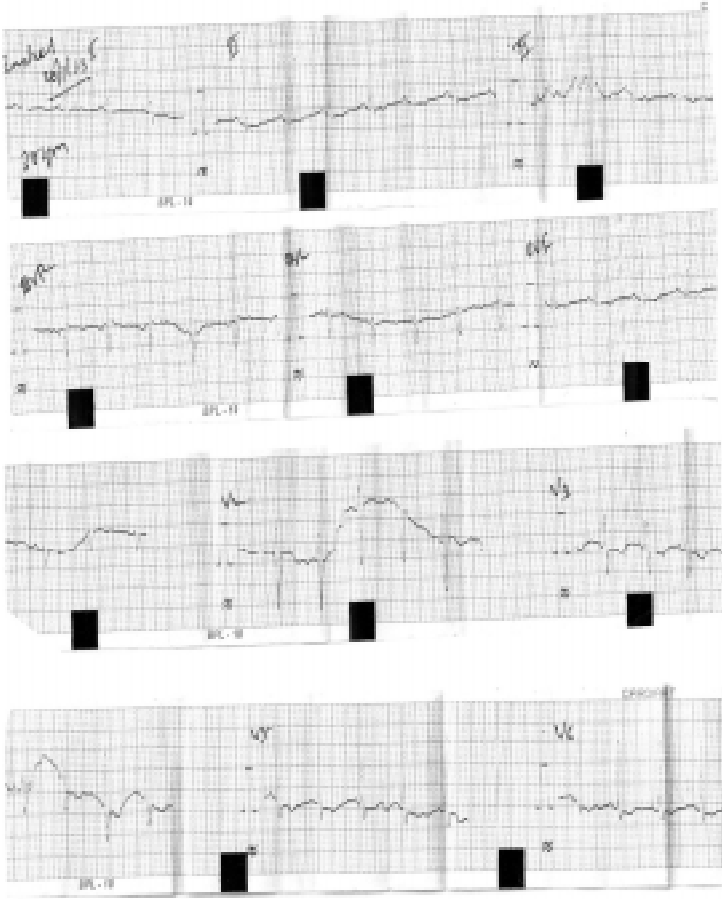
### DISCUSSION

Nitrobenzene, a pale yellow oily liquid, with an odour of bitter almonds is used as an intermediate in the synthesis of solvents, like paint remover. The first report of nitrobenzene poisoning came in 1886 and subsequent fatality reports followed<sup>1,2</sup>. Intoxication can

Department of Medicine, Swami Ramanand Teerth Rural Medical College and Hospital, Maharashtra 431517  
<sup>1</sup>MD, Associate Professor and Head and Medical Superintendent  
<sup>2</sup>MD, Assistant Professor  
<sup>3</sup>MD, Senior Resident

## ECG findings :

Date	Heart Rate	Axis & Rhythm	STT Changes	PR interval	QTc
20/01/2013	90/min	N/Sinus	T inversion3, avL, V2-V6	0.12	0.40
21/01/2013	75/min	N/Sinus	T inversion3, avL, V1-V3	0.12	0.36
22/01/2013	66/min	N/Sinus	T inversion3, avL, V1-V3	0.12	0.37
23/01/2013	60/min	N/Sinus	T inversion3, avL, V1-V3	0.12	0.34
24/01/2013	56/min	N/Sinus	T inversion3, avL, V1-V3	0.12	0.37
25/01/2013	50/min	N/Sinus	T inversion3, avL, V1-V4	0.12	0.54
26/01/2013	100/min	N/Sinus	T inversion3, avL, V1-V6	0.12	0.56



be accidental or suicidal, or the side effect of some drugs, including metoclopramide<sup>2</sup>. Accidental toxicity can occur in patients consuming well water with dangerously high levels of nitrites and nitrates<sup>3</sup>. The lethal dose is reported to range from 1 g to 10 g, by different authors<sup>4,5</sup>. A review of published reports does not provide any consistent reports regarding fatalities and dose of ingestion<sup>5</sup>. The toxic effects after ingestion are due to the rapid development of methaemoglobinaemia<sup>4</sup>, a condition in which the iron within the haemoglobin is oxidized from the ferrous ( $\text{Fe}^{2+}$ ) state to the ferric ( $\text{Fe}^{3+}$ ) state, resulting in the inability to transport oxygen and causes a brownish discoloration of the blood<sup>2</sup>. Once formed, methemoglobin can be reduced enzymatically either via an Adenine dinucleotide (NADH)-dependent reaction, catalysed by cytochrome b5 reductase, or an alternative pathway utilizing the nicotine adenine dinucleotide phosphate (NADPH)-dependent methemoglobin reductase system<sup>2</sup>.

Acute intoxication is usually asymptomatic up to the level of 10-15% of methemoglobin, showing only cyanosis. Beyond 20%,

headache, dyspnea, chest pain, tachypnea, and tachycardia develop. At 40-50%, confusion, lethargy, and metabolic acidosis occur leading to coma, seizures, bradycardia, ventricular dysrhythmia, and hypertension. Fractions around 70% are fatal. Anemic or G6PD-deficient patients suffer more severe symptoms<sup>2,4</sup>. Leukocytosis has been reported, with relative lymphopenia<sup>5</sup>. Other effects include hepatosplenomegaly, altered liver functions, and Heinz body haemolytic anaemia<sup>2,6</sup>. Nitrobenzene is metabolized to p-nitrophenol and aminophenol and excreted in urine, up to 65%, and in stools up to 15%, after five days of ingestion. Liver stomach, blood, and brain may act as stores and release it gradually<sup>6</sup>. Clues for diagnosis include a history of chemical ingestion, the characteristic smell of bitter almonds, persisting cyanosis on oxygen therapy without severe cardiopulmonary disease, low arterial oxygen saturation, with normal ABG (calculated) oxygen saturation. Dark brown blood that fails to turn bright red on shaking, which suggests methaemoglobinaemia and this is supported by the chocolate red colour of dried blood. Presence of nitrobenzene compounds may be confirmed spectrophotometrically and estimated by the butanone test of Schrenk, methemoglobin levels in the blood, and urinary presence of p-nitrophenol and p-aminophenol<sup>1,6,7</sup>.

Recommended treatment is based on the principles of decontamination and symptomatic and supportive management. Methylene blue is the antidote of choice for the acquired (toxic) methaemoglobinaemia. It is an exogenous cofactor, which greatly accelerates the NADPH-dependant methemoglobin reductase system and is indicated if the methemoglobin levels, which are more than 30%<sup>4</sup>. It is administered intravenously at 1-2 mg/kg (up to 50 mg dose in adults,) as a 1% solution over five minutes; with a repeat in one hour, if necessary. Methylene blue is an oxidant at levels of more than 7 mg/kg, and therefore, may cause methaemoglobinaemia in susceptible patients. It is contraindicated in patients with G6PD deficiency, because it can lead to severe haemolysis. Ascorbic acid is an antioxidant that may also be administered in patients with methemoglobin levels of more than 30%<sup>8</sup>. In recent studies, N-acetylcysteine has been shown to reduce methemoglobin, but it is not yet an approved treatment for methaemoglobinaemia. Exchange transfusion is indicated in severe cases<sup>4,8</sup>. Hyperbaric oxygen is reserved only for those patients who have a methemoglobin level >50% or those who do not respond to standard treatment<sup>2</sup>.

In this case, repeated low dose methylene blue helped in tiding over the fluctuating symptoms due to the release of nitrobenzene from the body stores, without exceeding the maximum dose. Fresh blood transfusion improved the oxygen carrying capacity and haemoglobin content, improving the patient symptomatically. Oral charcoal and purgation up to five days helped to eliminate the body stores of nitrobenzene and prevented secondary deterioration in the patient, as reported in some cases<sup>1,2</sup>. Taking care of nutrition, adequate urine output, and hepatoprotection prevented kidney and liver failure, which have been cited as late effects. Forced diuresis led to a rapid fall in methemoglobin levels and improved discoloration<sup>1,6</sup>. Ascorbic acid supplements are useful for follow-up management of methaemoglobinaemia<sup>9</sup>.

(Continued on page 32)

(Continued from page 30)

#### REFERENCES

- 1 Gupta G, Poddar B, Salaria M, Parmar V — acute nitrobenzene poisoning, *Indian Pediatr* 2000; **37**: 1147-8.
- 2 Dutta R, Dube SK, Mishra LD, Singh AP. Acute methemoglobinemia. *Internet J Emerg Intensive Care Med* 2008; **11**: 1092-4051.
- 3 Michelle, Kumar M — methemoglobinemia over view e Medicine from Web med. Available from: <http://www.emedicine.medscape.com/article/956528-overview>.
- 4 Chongtham DS, Phurailatpam, Singh MM, Singh TR — Methem-globinemia in nitrobenzene poisoning. *J Postgrad Med* 1997; **43**: 73-4.
- 5 International Programme on Chemical safety (IPCS) 2003(8.11) Nitrobenzene. Environmental health criteria 230. Geneva: WHO; Available from: <http://www.inchem.org/documents/ehc/ehc/ehc230.htm#8.1.1;#7.8>.
- 6 Wakefield JC. Nitrobenzene toxicological overview file format. PDF/Adobe Acrobat Version 1. Available form: [http://www.hpa.org.uk/web/HPAwebFile/HPAweb\\_C/1222068850334](http://www.hpa.org.uk/web/HPAwebFile/HPAweb_C/1222068850334) page 1-1.
- 7 Verive M, Kumar M — Methemoglobinemia: Differential diagnoses and workup, e medicine from web med. Available from <http://www.emedicine.medscape.com/article/956528-diagnosis>.
- 8 Verive M, Kumar M — Methemoglobinemia: Treatment and Medication, e medicine from web med. Available from: <http://www.emedicine.medscape.com/article/956528-treatment>.
- 9 Kaushik P, Zuckerman SJ, Campo NJ, Banda VR, Hayes SD, Kaushik R — Celecoxib-Induced Methemoglobinemia. *Ann Pharmacother* 2004; **38**: 1635-8.