

Case Report

Giant common bile duct stone

Vinay Pratap¹, D K Sinha², Sandip Kumar Aggrawal³, A K Kamal³, S Toppo³, Sumona Bose⁴

A forty year old female presented with pain in epigastrium, right hypochondrium and jaundice for the last one month. On examination the patient had mild pallor and icterus. Ultrasound of abdomen showed multiple stones in the gall bladder and a large stone in the common bile duct with dilated intrahepatic biliary radicals. She was posted for cholecystectomy and common bile duct exploration when a large stone of size approximately 8 X 5 cm was found to be impacted in the common bile duct along with multiple small stones. Cholecystectomy and common bile duct exploration was done.

[J Indian Med Assoc 2019; 117(8): 33]

Key words : Common bile duct stone.

Cholelithiasis is presence of gall stones in the common bile duct. Primary choledocholithiasis, formation of stone in the CBD is rare, occurs with bile duct stasis. Patients with CBD stones present with pain abdomen, jaundice, dark coloured urine, clay coloured stools, fever and chills (cholangitis), gall stone pancreatitis. Diagnosis is made by history, physical examination, blood tests, imaging (ultrasound, MRCP). Treatment consists of cholecystectomy with removal of CBD stone, ERCP with sphincterotomy.

CASE REPORT

A forty year old hindu female from Palamu (Jharkhand) presented in the outpatient department on 16/06/2012 with pain right upper abdomen for the last one month. She was also having yellowish discoloration of eyes and urine for last one month. She had similar pain three years back.

Examinations — On examination there was mild pallor and icterus. Her abdomen was soft with no organomegaly or any palpable lump. All routine investigations were done. Haematological examination showed Hb(10), Total Count (8300), P(64%), L(32%), E(02%), M(02%), B(0%), slightly increased bilirubin (1.4), increased alkaline phosphatase(504), SGOT and SGPT were within normal limits. Routine examination of urine and chest X-ray were normal. Abdominal ultrasound showed stone in gall bladder and common bile duct with IHBR dilatation.

After preparation she was posted for surgery on 27/06/2012. Abdomen was opened by right paramedian incision, gall bladder was found to be contracted and fibrosed, filled with multiple stones. Common bile duct was dilated. It was opened and a large stone of size 8X5 cm was taken out along with multiple small stones (Fig 1).

Cholecystectomy was done by fundus first method. Common bile duct was washed with normal saline. Postoperative period was uneventful.

DISCUSSION

In most of the cases of choledocholithiasis solitary stone is found in the common bile duct. Walter and Snell reported solitary stone in $\frac{2}{3}$ of their cases¹. Mayo Robson and Dobson counted 88²

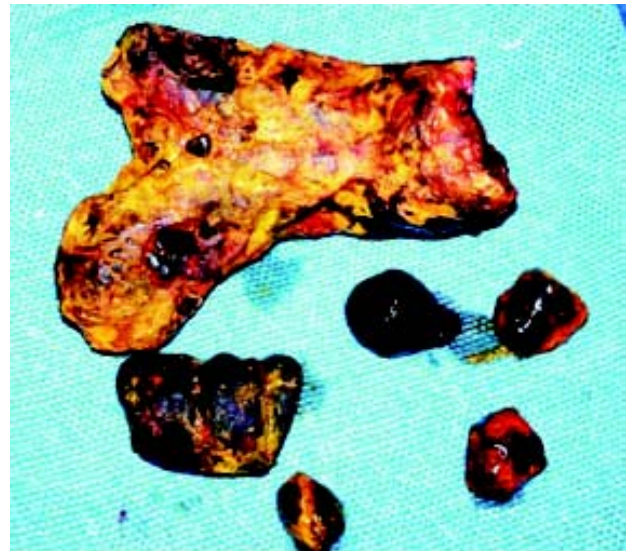


Fig 1 — Large CBD stone along with multiple stones

and Judd and Marshall^{3,4} more than 100. In most case a stone lies in the lower part of common bile duct. Giant gall bladder stone have been reported; one measuring 4 inches⁵ in circumference and another 6 $\frac{1}{2}$ inches long and 6 inches thick⁶ have been reported. Bahuleyan reported a giant common bile duct stone measuring 6.5 X 3 cm⁷.

REFERENCES

- 1 Walter and Snell: "Diseases of The Gall Bladder and Bile Ducts." W. B. Saunders Company, Philadelphia and London, 1990. Quoted by Aird (1958).
- 2 Mayo-Robson and Dobson: "Diseases of The Gall Bladder and Bile Ducts." London, 1904. Quoted by Aird (1958).
- 3 Judd ES, Marshall JM — Gall stones in ampulla of Vater. *J Amer Med Assoc* 1980; **95**: 1061-4.
- 4 Judd ES, Marshall JM — Gall stones in the common bile duct. *Arch. Surg* 1931; **23**: 175-81.
- 5 Lichtman SS — Diseases of the Liver. Gall Bladder and Bile Duct. 3rd Edition. Lea and Febiger, Philadelphia 1953; 1198.
- 6 Bockus HL — Gastro-Enterology." Vol III, 2nd Edition, WB Saunders Company, Philadelphia, London & Toronto, 1965; 954.
- 7 Bahuleyan CK — Giant common bile duct calculus. *Ind J Surg* 1975; **37**: 82.

Department of Surgery, Rajendra Institute of Medical Sciences, Ranchi 834009

¹MS, FICS, FMAS, FIAGES, Associate Professor, and Corresponding author

²MS, SRF-CSIR, Associate Professor

³MS, Assistant Professor

⁴MBBS, Junior Resident (Academic)