

## Case Report

# Dermatofibrosarcoma protuberans of the vulva — a case report

Hem Prabha Gupta<sup>1</sup>, Shalini Dwivedi<sup>2</sup>

A 34 years lady presented with swelling over Rt Labia Majora since last three months which was gradually increasing, painless, not adherent to deeper tissue. Wide excision of the mass was done & histopathological report was Dermatofibro Sarcoma Protuberance Vulva. Which is extremely rare with low malignant potential. The patient is doing well after operation.

[J Indian Med Assoc 2019; 117: 24 & 26]

**Key words :** Dermatofibro Sarcoma Vulva, Excision, MoH's Operation.

**D**ermatofibro Sarcoma Protuberance of Vulva is a very rare tumour. It occurs in adults in their thirties. The incidence is 0.8-4.5/ million per year<sup>1</sup>. In 2 to 5% of cases it can metastasise with low malignant potential. Although it behaves like benign Tumour its recurrence is very common. As such this tumour is found on the Torso. But it can be found on the arms, legs, head & neck also & vulva is a rare site.

### CASE REPORT

Mrs X a 34 years old female, P3+0 with two living issue visited Gynae OPD at Era's Medical College and Hospital, Lucknow on 21st November 2012 with chief complaints of swelling over the right Labia Majora since last three months. It was painless and was gradually increasing in size.

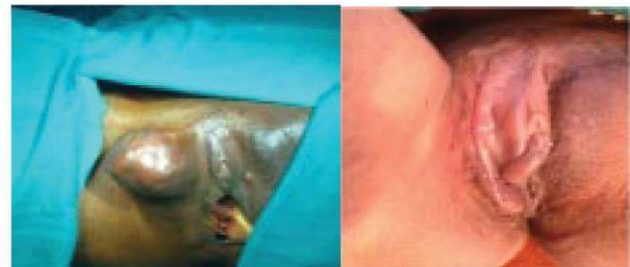**Past history** — She had similar swelling over the mons Pubis 5 years ago, for which surgical excision was done but she did not have the histopathological report.

The patient was hospitalized. The patient was of average built and nutrition. There was no lymphadenopathy, systemic examination revealed no abnormality.

**Local examination** — A big transverse surgical scar was present over the Mons Pubis healed by secondary intention. A well circumscribed swelling of 3x2 inches was present on the upper part of the right Labia Majora, the colour of the skin overlying the swelling was normal. It was firm and mobile from side with regular well defined margins. The swelling was not fixed to deeper structures. On vaginal examination and per speculum examination cervix and uterus were normal.

**Investigations** — All investigations including Hb% viral markers, blood sugar levels, X-ray chest, and complete urine examination were normal.

**Management** — Wide excision of the swelling was done under spinal anaesthesia on 29th November 2012. Postoperative recovery was uneventful. Histopathology report confirmed the diagnosis of DERMATOFIBROSARCOMA PROTUBERANS. After six months she came for check up she was doing well without any



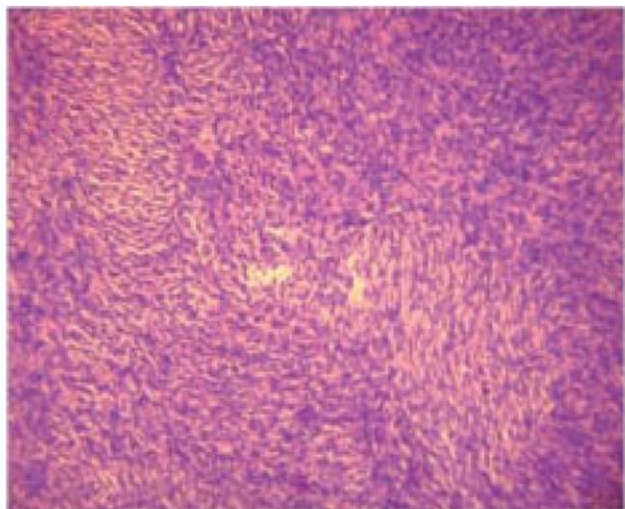
Before Operation

After Operation

problem, on next subsequent check ups. She had no problem.

### DISCUSSION

DFSP of the Vulva is extremely rare and Uncommon<sup>6</sup>. It is a low grade Sarcoma of the Dermis, Clinically appears encapsulated but microscopically has Tumour projections well away from the central nodule. In 1981 Barnhill DR & Boling R *et al* reported it as a fifth reported case of this Neoplasm<sup>5</sup>. In 1981 MH Saltan reported the case with a comment that is has not been previously reported in Vulva<sup>6</sup>. According to Marcia MD *et al*, it is seldom seen in Vulva and only 29 cases have been reported<sup>7</sup> & in their institution 13 cases were reported in 29 years (1978-2007).



Histopathological picture : Showing Storiform Pattern

Department of Obstetrics & Gynaecology, Era's Lucknow Medical College & Hospital, Lucknow 226003

<sup>1</sup>MBBS, MS, MNAMS, FICS (Indian section), Professor and Corresponding author

<sup>2</sup>MBBS, Junior Resident II

(Continued on page 26)

(Continued from page 24)

This tumour is of intermediate grade of malignancy with tendency of local recurrence. It rarely metastasises<sup>2</sup> but management should be multidisciplinary. MOH's micrographic surgery is generally advocated to ensure precise margin control. Survival rate ranges from 91-100% & local recurrence rate upto 20-49% have been reported<sup>3</sup>. Therefore follow up is recommended. It is not clear what causes this type of malignancy. It is thought that injury or trauma to the skin may be the predisposing factor. There is no evidence to suggest that it is hereditary. It occurs in all ages and races, more likely between the age 20-50 years. It results from new mutation that occurs in the body cell after conception and is found only in Tumor Cells. This type of genetic change is called somatic mutation and is not generally inherited. The general prognosis is excellent<sup>4</sup>. In the past, recurrence rate was high but with the introduction of MOH's operation recurrence has decreased. The cure rate is 98%, usually recurs in three years of treatment, so follow up during first three years is in 3-6 months and after three years annual check up is recommended life long. Because of Rarity this case is being re-

ported, the patient is doing well after one & half years of surgery.

#### REFERENCES

- 1 Gloster HM Jr1 — Dermatofibrosarcoma protuberans. *J Am Acad Dermatol* 1996; **35**: 355-74.
- 2 Mitchel S, Hoffman — Malignancies of the Vulva. Te Linde's Operative Gynaecology Ninth Edition. 1334.
- 3 Karlen JR, Johnson K, Kashkarri — Dermatofibrosarcoma protuberans of the vulva - A case report. *J. Reproduct Med* 1996; **41**: 267-9.
- 4 Olejek A, Kozak-Darmas I, Gajewska A, Gabriel A, Zajecki W — Dermatofibrosarcoma protuberans of the vulva. *Wiad Lek* 2008; **61**: 232-5.
- 5 Barnhill DR, Boling R, Nobles W, Crooks L, Burke T — Vulvar dermatofibrosarcoma protuberans. *Gynaecol Oncol* 1988; **30**: 149-52.
- 6 Soltan MH — Dermatofibrosarcoma protuberans of the vulva - Case report. *Br J Obstet Gynaecol* 1981; **88**: 203-5.
- 7 Edelweiss M, Malpica A — Dermatofibrosarcoma protuberans of the vulva: a clinicopathologic and immunohistochemical study of 13 cases. *Am J Surg Pathol* 2010; **34**: 393-400. doi: 10.1097/PAS.0b013e3181cf7fc1.