

## Case Report

# Astrocytoma arising in a dermoid cyst of the ovary and coincidence of Rhinosporidiosis of nose & nasopharynx in an adolescent girl

Mahamaya Sharma<sup>1</sup>, Subrata Lahiri<sup>2</sup>

**Malignant transformation of mature cystic teratoma of ovary mainly affects squamous epithelium. The neuroectodermal component undergoing malignant change is a highly exceptional event. Reports on astrocytic tumour arising in a mature and immature teratoma in ovary are extremely rare and therefore, guideline on treatment is not clear. In view of exceptionally rare incidence, this tumour needs documentation and formulation of treatment guideline. This report documents a case of 'Astrocytoma grade III arising in a mature cystic teratoma of the ovary in an adolescent girl and coincidence of Rhinosporidiosis of nose and nasopharynx'.**

[J Indian Med Assoc 2018; 116: 41-2 & 44]

**Key words :** Astrocytoma grade III, malignant transformation, ovarian mature cystic teratoma, rhinosporidiosis.

Malignant transformation of mature cystic teratoma of ovary is reported in less than 2% of cases. Although all elements can undergo this transformation, it is mostly seen in squamous epithelium. Malignant transformation mainly affects post-menopausal woman. The neuroectodermal component undergoing malignant change is a highly exceptional event. Here, we describe a rare case of mature cystic teratoma of the ovary with malignant transformation to astrocytoma grade III. Simultaneous occurrence of rhinosporidiosis of nose and nasopharynx also has been documented.

### CASE REPORT

A 17 years adolescent girl presented gradual swelling of lower abdomen of three months duration. There were no systemic complaints except a red flashy mass in nose and nasopharynx. An ultrasonography and computerised tomography scan done showed a large cystic mass arising from right ovary and measuring 27 cm in its greatest diameter with irregular outline. Multiple foci of calcification and daughter cysts were seen inside. No ascites were noted. She was anaemic (Hb-8.9 gm %) and had elevated CA-125 level (55.2 µ/ml). A clinical diagnosis of benign ovarian teratoma was made and right salpingo-oophorectomy was done. No regional lymphadenopathy or omental nodules were palpated.

### Pathologic findings :

Macroscopic examination showed a large cystic mass measuring 26x15 x13 cm filled with serous fluid of 1.5 litres. Cut section of the mass revealed multiple daughter cysts with hair, sebaceous material and cartilage inside. Multiple solid nodules were projecting from outer surface. The capsule remained intact. Microscopy revealed cystic spaces lined with epidermis and glandular epithelium. The cyst wall contains sebaceous and sweat glands, hair follicles, bronchial epithelium, serous & mucinous glands, cartilage,

bone, smooth muscle, fibrous and fatty tissue, neural tissue and ganglion cells of sympathetic type (Fig 1).

The solid nodules on the surface and more solid areas of the cyst showed glial tissue and choroid plexus (Fig 2). Some foci were cellular (Fig 3 & Fig 4) with moderate nuclear pleomorphism and hyperchromasia, vascular proliferation and mitotic activity. The histopathological diagnosis was mature cystic teratoma with malignant transformation to astrocytoma (grade III, World Health Organisation 1993 classification). Since the tumour was completely restricted to ovary, no adjuvant therapy was given. Although she was advised chemotherapy with etoposide, cisplatin & bleomycin by referral cancer centre keeping the probability of peritoneal implants, yet she was put off chemotherapy for her limited stage I a tumour. Furthermore, the patient was evaluated regularly by post-operative clinical, laboratory and imaging studies and remained negative.

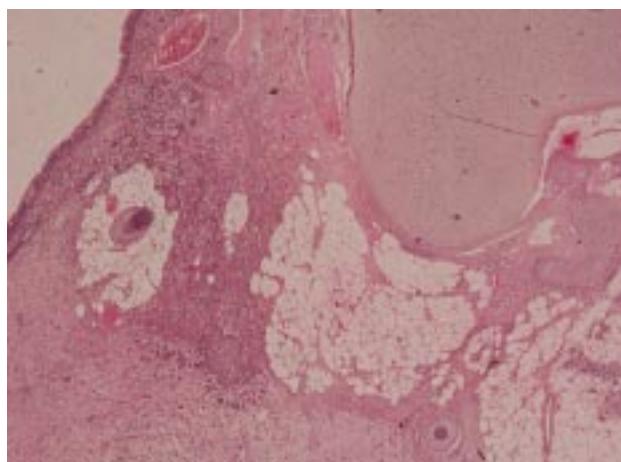


Fig 1 — The tumour is composed of glandular epithelium, hair follicles, adipose and fibrous tissue, cartilage, ganglion cells of sympathetic type and mature glial tissue. (H&E x 200)

Department of Pathology, Central Hospital, South Eastern Railway, Garden Reach, Kolkata 700043

<sup>1</sup>MD (Pathol), Senior Divisional Medical Officer

<sup>2</sup>MD (Obstet & Gynaecol), Additional Chief Health Director (Obstet & Gynaecol), Department of Obstetrics & Gynecology

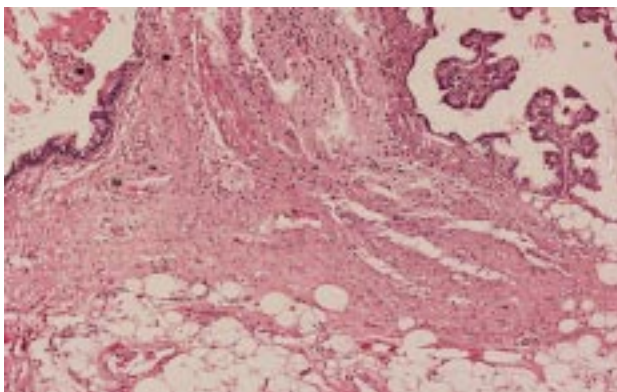


Fig 2 — The tumour is composed of neural tissue and choroid plexus along with glandular epithelium and adipose tissue. (H&E x 100)

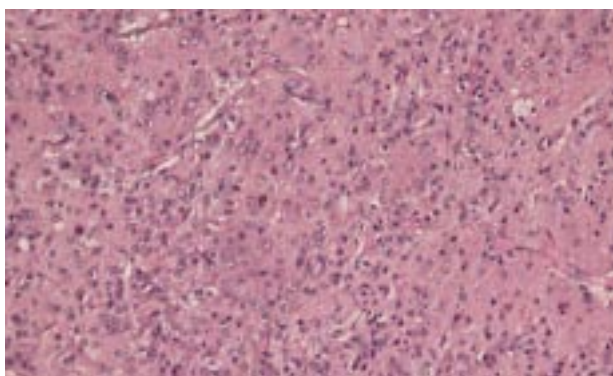


Fig 3 — Astrocytoma, grade III (H&E x 200)

#### Associated findings :

Red fleshy mass coming through nose and nasopharynx, was excised 15 days before salpingo-oophorectomy. Histopathological examination of excised specimen showed the presence of rhinosporidiosis.

#### DISCUSSION

Teratoma with malignant transformation (TMT) refers to the occurrence of somatic non-germ cell malignancy within teratoma. Malignant transformation of teratoma in ovary is reported in less than 2% of benign cystic teratomas. This is usually observed in post menopausal patients. The most common malignant transformation is squamous cell carcinoma. Benign nervous tissue is present in at least four-fifths of all teratomas<sup>1,2</sup>. However the malignancy of neural element is the least common event. To the best of our knowledge only 21 cases including this one have been documented in the literature<sup>1-10</sup>. Among these, 14 were developed within a mature cystic teratoma. Glioblastoma multiform (astrocytoma, grade IV) was the predominating type (13 cases) whereas fibrillary astrocytoma and pilocytic astrocytoma of grade I & II was reported in seven cases. However, to the best of our knowledge, grade III astrocytoma (WHO classification) arising within a mature cystic ovarian teratoma has not been reported in the literature.

Astrocytic and ependymal tissue, nerve ganglia of sympathetic type, nerve bundles accompanied by Schwann cells and choroid plexus containing cerebrospinal fluid may be seen within mature teratomas<sup>1</sup>.

Astrocytoma of grade III of central nervous system designated by World Health Organization is an intermediate lesion between

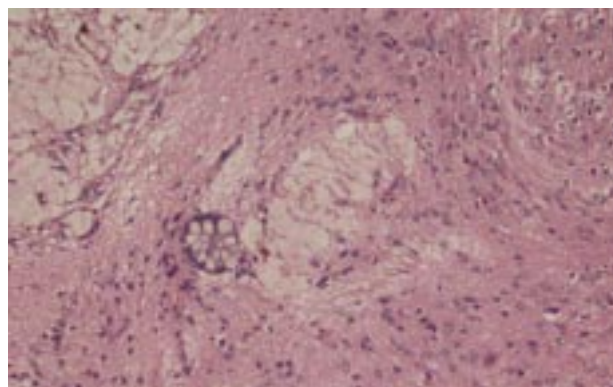


Fig 4 — Glandular epithelium is intermingled with Astrocytoma. (H&E x 100)

well differentiated astrocytoma of grade I & II and glioblastoma multiform of grade IV. This is one that typically exceeds well differentiated astrocytoma in terms of cellularity, nuclear pleomorphism and hyperchromasia, vascular proliferation and mitotic activity but lacking marked cellularity and neurosis of glioblastoma multiform. The present case qualifies all the features of grade III astrocytoma.

Peritoneal implantation is the common mode of spread of TMT. The malignant glial tissue, although a rare event, have the capability to settle at ectopic site ie, peritoneal cavity as gliomatosis peritonei from mature ovarian teratoma<sup>11</sup> and peritoneal glioblastoma from immature ovarian teratoma even after several years of primary surgery<sup>12</sup>. It is well documented in the literature that astrocytic tumor of grade I, II & IV arising in a benign cystic teratoma, complete excision of the tumour limited to ovary provides disease free survival without adjuvant chemotherapy<sup>2,3,9</sup> like the present case. We found support in the literature to withdraw adjuvant chemotherapy for her limited stage I a tumour. Today, 33 months after the surgery she is healthy and doing well.

Rhinosporidiosis is a chronic granulomatous disease and caused by *Rhinosporidium seeberi*. Rhinosporidiosis is endemic in eastern and northern India. Nose and nasopharynx is the commonest site. The presence of rhinosporidiosis in this case may be just concurrent. Review of literature did not reveal any association with TMT.

#### REFERENCES

- Berger N, Pochaczewsky R — Astrocytoma containing ovarian teratoma in childhood. *Am J Roentgenol Radium Ther Nucl Med* 1969; **107**: 647-51.
- Bjersing L, Cajander S, Rogo K, Ottosson UB, Stendahl U — Glioblastoma multiform in a dermoid cyst of the ovary. *Eur J Gynecol Oncol* 1989; **10**: 389-91.
- Thurlbeck WM, Scully RE — Solid teratoma of the ovary: a clinicopathological analysis of 9 cases. *Cancer* 1960; **13**: 804.
- Malkasian GD Jr, Symmonds RE, Dockerty MB — Malignant ovarian teratomas: report of 31 cases. *Obstet Gynecol* 1965; **25**: 810-14.
- Shirley RL, Piro AJ, Crocker DW — Malignant neural elements in a benign cystic teratoma. A case report. *Obstet Gynecol* 1970; **37**: 402-07.
- Nishida T, Sugiyama T, Oda T, Tazaki T, Yakushiji M, Kato T — Prognostic significance of glioblastoma element in ovarian immature teratoma. *Acta Obstet Gynecol Jpn* 1984; **36**: 1095-99.
- Kleinman GM, Young RH, Scully RE. Primary neuro-ectodermal tumours of the ovary. *Am J Surg Pathol* 1993; **17**: 764-78.
- Der Boon J, van Dijk CM, Helfferich M, Peterse HL — Gli-

(Continued on page 44)

(Continued from page 42)

- blastoma multiform in a dermoid cyst of the ovary. A case report. *Eur J Gynecol Oncol* 1999; **10**: 187-8.
- 9 Skopelitou A, Mitselou A, Michail M, Mitselos V, Stefanou D — Pilocytic astrocytoma arising in a dermoid cyst of the ovary: a case presentation. *Virchows Arch* 2002; **440**: 105-06.
- 10 Biskup W, Calaminus G, Schneider DT, Leuschner I, Gobel U — Teratoma with malignant transformation : experiences of the cooperative GPOH protocols MAKEI 83/86/89/96. *Klin Padiatr* 2006; **218**: 303-08.
- 11 Gocht A, Lohler J, Scheidel P, Stegner H-E, Saeger W — Gliomatosis peritonei combined with mature ovarian teratoma. Immunohistochemical observations. *Pathol Res Pract* 1995; **191**: 1029-35.
- 12 Trabelsi A, Conan-Charlet V, Lhomme C, Morice P, Duvillard P, Sabourin JC — Peritoneal glioblastoma: recurrence of ovarian immature teratoma (report of a case). *Ann Pathol* 2002; **22**: 130-33.