

Original Article

A long term follow up Series of Parkinsonian Syndrome with Chronic Subdural Haematomas — A Rare Presentation

Sudipta Chatterjee¹, Kanchan Sarkar Chakravarty², Sucheta Chatterjee³, Abhirup Chakraborty⁴, Chitrita Chatterjee⁵

Parkinson's disease is a common clinical entity. The diagnosis of this syndrome is relatively easy. Parkinsonian plus syndrome includes other clinical features in addition to classical Parkinsonian signs which also includes secondary parkinsonism. Chronic subdural haematoma is also a common condition in Neurosurgical practice. Relationship between parkinsonian syndrome and Chronic subdural haematoma is interesting.

[J Indian Med Assoc 2018; 116: 53-5]

Key words : Parkinson's disease, Parkinsonian Plus Syndrome, chronic subdural Haematomas.

Parkinson's disease is a common clinical entity, characterized by tremor, rigidity, akinesia, postural instability-forming the acronym TRAP Syndrome. The diagnosis of this Syndrome is relatively easy. Parkinsonian Plus Syndrome includes other clinical features in addition to classical parkinsonian signs which also includes secondary Parkinsonism⁵. Chronic subdural haematoma is also a common condition in neurosurgical practice which usually presents with fluctuation in the level of consciousness, headache, nausea, vomiting, lethargy, hemiparesis, Memory deficit. Relationship between Parkinsonian Syndrome and Chronic subdural Haematoma is interesting. Parkinsonian patients are more prone to develop chronic subdural haematoma. On the other hand Chronic subdural haematoma can cause parkinsonism although the mechanism is open to debate. Only one such case has been reported by Harding³. In most of the cases there is progressive neurological deterioration in Parkinsonian patients due to development of Chronic subdural haematoma. Awareness of this concept is a must amongst clinicians. Out Of these three such cases of progressive neurological deterioration in parkinsonian patients, reported here, diagnosis in these two cases were delayed due to unawareness of this condition. The whole spectra has emerged as Chronic subdural haematoma related Parkinsonism³. In 1158 cases of chronic Subdural haematomas noted over a period from

2004 to 2014 in SSKM Hospital, Medical College, R G Kar Medical College and Nightengle Hospital, only three cases have shown chronic Subdural haematoma related Parkinsonism. Intensive net search and review of world literature revealed 26 similar cases of Chronic subdural haematoma related Parkinsonism. To the best of our knowledge, the cases reported here are the 27th, 28th and 29th similar cases (Table 1).

MATERIALS AND METHODS

1158 cases of chronic Subdural haematomas have been noted over a period from 2004 to 2014 in SSKM Hospital, Medical College, RG Kar Medical College and Nightengle Hospital. Out of these, only three cases have shown chronic Subdural haematoma related Parkinsonism. Intensive net search and review of world literature revealed 26 similar cases of Chronic subdural haematoma related Parkinsonism. To the best of our knowledge, the cases reported here are the 27th, 28th and 29th similar cases.

Case 1:

This 68 year old female patient was admitted in neurosurgery unit with impaired consciousness (GCS-E1V2M4), right sided hemiparesis, headache with vomiting in the early hours and incontinence of urine. Patient had an attack of multiple lacunar infarcts two years back and was followed by tremor at rest and rigidity of right arm and leg and bradykinesia. She was hypomimic. Speech was slow and dysarthric. There was progressive difficulty in walking including retropulsion. She had history of repeated falls. She was diagnosed to have secondary Parkinsonism and levodopa was prescribed. She responded well initially. Later on she developed progressive dementia. Minimental scoring was 23. Pacitane and aspirin were added. This continued for about six months, till a repeat CT was done showing left parietal Chronic subdural

Department of Neurosurgery, RG Kar Medical College & Hospital, Kolkata 700004

¹MCh (Neurosurgery), Associate Professor

²MCh (Neurosurgery), Associate Professor of Neurosurgery, Medical College & Hospital, Kolkata 700073 and Corresponding author

³MD (Psychiatry), Postgraduate student, KIMS, Bhubaneswar 751024

⁴MS (General Surgery), Postgraduate Student, RG Kar Medical College & Hospital, Kolkata 700004

⁵MD (Microbiology), Professor of Microbiology, NRS Medical College & Hospital, Kolkata 700014

Table 1 — List of previously published cases of Chronic subdural haematoma related Parkinsonism						
Author	Age at Onset sex	Chronic Subdural heamatoma	Parkin-sonian	Other symptoms	Response to levodopa	Surgical outcome
Samiy	52,m	left	T,R,G	NA	NA	Complete Remission
Chon 1977	62,m	Right	T,H	He,C,F	NA	Complete Remission
Sandyk 1982	66,m	left	T,H,B	He,C,F	Yes	Complete Remission
Sandyk & Kahn 1983	38,f	Right	T,H,B,R,G	He,C	NA	Complete Remission
Glatt 1983	74,m	Bilateral	H,B,R,G	M	NA	Complete Remission
	72,m	Bilateral	T,H,B,R,G	NA	NA	Marked Improvement
Harding 1984	78,f	Left	T,H,B,R,G	C,I		Complete Remission
Accardi 1985	48,m	Bilateral	T,B,R	He,F	NA	Complete Remission
Krul & Woke 1987	83,m	Bilateral	T,H,B,R,G	I	NA	Partial Remission
Pau 1989	60,f	Right	B,R	He,L	NA	Partial Remission
Ammenomori 1989	58,m	Right	T,H,B,R,G	He	NA	Complete Remission
Hageman & Horstink 1994	66,m	Left	T,H,B	NA	NA	Spontaneous Remission
Sonada 1996	75,m	Left	T,H,R,G	C,Hemi	Yes	Complete Remission
Wiest 1998	63,m	Right	T,H,B,R,G	NA	No	Compltr Remission
	70,m	Bilateral	B,R,G	I,S	NA	Recovery to premorbid Function
	82,m	Right	T,B,G	Apathy	No	Recovery to premorbid Function

m- male, f-female, T- tremor, H- hypomimia, B-bradykinesia, R-rigidity, G-Gait problems, He-Headache, C-confusion, I-incontinence, L- lethargy, Hemi- hemiparesis, S- somnolence

haematoma with midline shift with evidence of acute bleed at places. Haematoma was evacuated and drained via left parietal burr hole under GA. Patient responded well and returned to the GCS score of E4V4M5, 14 days after operation.

Case 2 :

This 60 year old male patient had a 3 year old history of idiopathic Parkinson's disease with no history of trauma. He was been treated with levodopa and bromocriptine. About a week prior to admission, patient developd headache, vomiting, dementia, exaggeration of Parkinsonian symptoms on right side, including resting tremor. On admission patient had right side hemiparesis and his GCS was E2V3M3 with the CT showing left parietal Chronic subdural haematoma with midline shift. Haematoma was evacuated and drained via left parietal burr hole craniectomy under GA. Patient recovered well to the GCS – score of E4V5M5, ten days after operation. His general condition was not improving. On the twentieth day he had haematuria. He was referred to urologist. Following investigations it was found that the patient had carcinoma of bladder along with

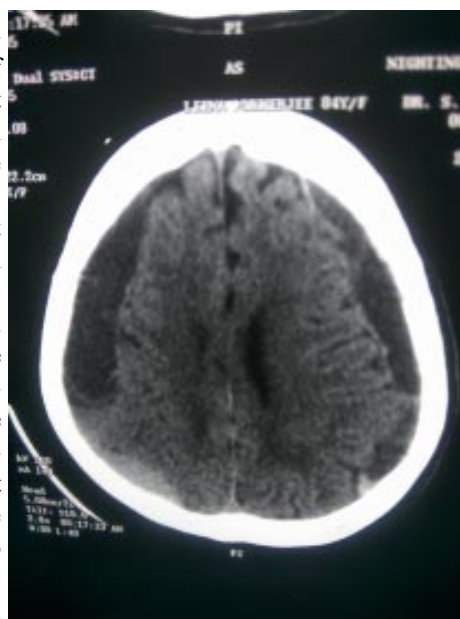


Fig 1 — Showing CT scan of bilateral chronic subdural haematoma

hydroureter and hydronephrosis. Gradually the patient developed renal failure. Nephrologist suggested dialysis. But the party did not give consent for it. The patient died.

Case 3 :

This patient, 78 years old female, with history of trivial fall, presented with impaired memory and features of Parkinsonian syndrome. Patient developed this classical symptoms for last two months. CT Scan showed bilateral Chronic Subdural haematoma (Fig 1). GCS was E4 V3 M5. Operation was carried out with bilateral frontal and parietal burr hole on each side. Her conscious level improved over fifteen days to GCS=15. Tremor persisted but rigidity and bradykinesia improved with time.

DISCUSSION

Beginning of movement disorders started from James Parkinson's essay on Shaking Palsy in 1817. He described in his words "involuntary tremulous motion, with lessened muscular power, in parts not in action and even when supported; with a propensity to bend the trunk forward, and to pass from walking to a running pace, the senses and intellect being uninjured". Ironically his essay has no reference to rigidity or to slowness of movement⁸. Presently

Parkinson's disease includes clinical and pathological criteria. Clinical criteria includes bradykinesia, rigidity, resting tremor, postural instability and usually positive response to levodopa therapy. Pathological criteria includes neuronal loss, gliosis in substantia niagra and other pigmented brainstem nuclei. Moreover there is a class of syndrome where Parkinsonian signs are essential but not the only clinical feature – these related conditions are called Parkinsonian – plus which also includes secondary Parkinsonian syndromes. PPs phenotypes include mainly bradykinesia and rigidity aong with additional features like pyramidal dysfunction, eye movement problems, dementia, behavioural changes and autonomic failure. Postural instability is usually present but resting tremor is usually absent⁵. Subdural haematoma can

cause dystonia, chorea, and Secondary Parkinsonism^{5,6}. Movement disorders are most commonly associated with Chronic subdural haematoma⁶. Reviewing the literature and net search 19 patients with Chronic subdural haematoma related Parkinsonism cases have been identified for whom the data are available. They have been summarized in Table 1. Seven other similar patients have been published in Japanese, Italian and Portuguese literature^{1,2,3,4}.

In the previous 19 patients (16 male, 3 female; age range; 38 to 83 year unilateral in 12 cases and bilateral chronic subdural haematoma in 7 cases), 18 patients underwent surgical evacuation and showed rapid improvement. Complete Remission was possible in 11 cases. Most of these patients had progressive neurological deterioration in Parkinsonian patients due to development of chronic subdural haematoma. In only one case, described by Harding³, Chronic subdural haematoma was causing Parkinsonism.

In the present two cases, first case had a history of lacunar infarct followed by development of Parkinsonism leading to concept of vascular Parkinsonism which has found resurgence in recent years. Here lacunar infarct commonly involve corpus striatum. Lack of awareness that chronic subdural haematoma can lead to progressive neurological deterioration in Parkinsonian patients, made diagnosis delayed as repeat CT was not advised early. In the second case, CT was advised early and chronic subdural haematoma was diagnosed. Both these patients had remarkable improvement on evacuation. Contrary to usual PPS features, resting tremor was absent in both cases. In third case patient was primarily diagnosed to have parkinsonism for last six months synonymous with history of fall. CT scan was never advised except in last stages when she became disoriented.

Factors causing chronic subdural haematoma in Parkinsonism can be explained by the fact that these patients fall frequently (due to retropulsion) sustaining trivial trauma to head due to difficulty in maintaining balance and coincidental cerebral atrophy, in older ages, widening of subdural space expose bridging veins to risk of rupture. First case can be explained by trivial trauma and Chronic subdural haematoma. Cerebral atrophy, in older ages can explain second case. Haematoma formation is gradual, aggravated by repeated micro haemorrhages from friable capillaries of neo membranes².

Mechanism of Chronic subdural haematoma produc-

ing Parkinsonism remain unclear. Direct mechanical compression, vascular and metabolic disturbances are possible causes. Distortion and compression of mid-brain and basal ganglia can disturb substantia nigra, nigro pathways and striatum, leading to these effects. Thus the whole spectra has emerged as Chronic subdural haematoma related Parkinsonism. Over period of ten years, 1158 cases of chronic Subdural haematomas have been noted. Out of these only three cases have shown chronic Subdural haematoma related Parkinsonism. Intensive net search and review of world literature revealed 26 similar cases of Chronic subdural haematoma related Parkinsonism. To the best of our knowledge, the cases reported here are the 27th, 28th and 29th similar cases.

Conclusion :

So in all patients with unexplained progressive neurological deterioration in Parkinsonian patients or with rapidly progressive courses of new onset Parkinsonism, repeat CT studies of brain should be done immediately to exclude curable causes of secondary Parkinsonism, especially Chronic subdural haematoma. Prognosis of Chronic subdural haematoma related Parkinsonism is favourable after adequate surgical treatment and awareness of this entity is a must for attending physicians, neurophysicians and neurosurgeons.

REFERENCES

- 1 Cohn DF — Das Parkinson syndrome, hervorgerufen durch intrakraniellraumfordernde Prozesse. *Nervenarzt* 1977; **48**: 383-5.
- 2 Giuffrè R — Physiopathogenesis of Chronic subdural haematomas; A new to an old problem. *Riv Neurol* 1987; **5**: 298.
- 3 Harding AE — Subdural haematoma in two patients with chronic neurological disorders. *BMJ* 1984; **288**: 1986-7.
- 4 Jankovic J — Treatment of parkinsonian syndromes, In; Kurlan R (ed) Treatment of movement disorders. Lippincott, Philadelphia 1995, 85-115.
- 5 Jankovic J — Parkinsonian Plus Syndrome. *Movdis* 1989; **4**: S95-S119.
- 6 Kotagal S, Shuter E, Horenstein S — Chorea as a manifestation of Bilateral subdural haematoma in an elderly man. *Arch Neural* 1981; **28**: 195.
- 6 Madarame H, Kimura M, Takahashi A — Parkinsonism and Bilateral subdural haematoma Report of three cases. *Shinkei Naika* 1989; **23**: 269-373 (Japanese).
- 7 Schisano G, Cimino R — Ematoma subdural cronico a sintomatologia extrapyramidale acuta. *Rass Int Clin Ter* 1970; **50**: 898-901 (Italian).
- 8 Sherwood, Neely, Jones Parkinson J — An essay on the shak- ing palsy. London : 1817.