

Case Series

Cardiovascular Manifestations of Dengue Fever — Two Case Report and Review article

Kanak Kumar Mitra¹, Lipika Adhikari², Jyotirmay Pal³, Uday Sankar Das⁴,
Palash Mondal⁴, Tapobrata De⁵

Dengue is one of the most important viral diseases affecting human beings. The majority of symptomatic infections result in a relatively benign disease course. However, a small proportion of patients develop severe clinical manifestations due to platelet and endothelial dysfunction, immunological derangement with increased capillary permeability causing bleeding, hypovolaemic shock and cardiovascular collapse. Evidence is increasing that dengue can also cause myocardial impairment, arrhythmias and, occasionally, fulminant myocarditis. Here we are reporting two cases of Dengue fever presenting with Bradyarrhythmias (Atrioventricular Block) and another with myocarditis and heart failure. No antiviral agent is available till now and treatment remains supportive with judicious fluid replacement for patients with severe disease. Understanding of cardiovascular hemodynamics in Dengue is important in the management specially during life threatening situation. In this Review Article we will outline the current understanding of the cardiovascular manifestations of dengue fever from the available literatures and conclude with a discussion of the possible therapeutic implication.

[J Indian Med Assoc 2018; 116: 32-5]

Key words : Dengue, Bradyarrhythmias.

Dengue is one of the most important mosquito-borne viral diseases in the world¹. It is an acute febrile illness caused by any of the four serotypes (1,2,3 or 4) of a virus from the genus flavivirus, called Dengue virus. Cardinal clinical features of Dengue are fever, Rash, Arthralgia, myalgia, retroorbital pain, Hypovolemic shock or in extreme cases hemorrhagic shock. Cardiac involvement in Dengue is not very common. Cardiac manifestations in dengue virus infection can range from asymptomatic sinus bradycardia to life threatening myocarditis and Ventricular arrhythmias²⁻⁸. We are reporting 2 cases, reviewed the literature and discussed the implications of cardiac complications in dengue patients. A better understanding of cardiac complications will potentially improve the treatment of dengue illness by avoiding otherwise preventable morbidity and mortality in the affected patients.

CASE REPORT

Case 1:

A 11 year old boy was transferred to Cardiology Dept, RG Kar Medical College & Hospital for evaluation of sinus bradycardia with history of fever for 5 days with myalgia without any form of bleeding manifestations. Neither the boy had any symptoms related to bradycardia (Vertigo, syncope or shortness of breath) nor he had any prior history of cardiac diseases. No family history of cardiac diseases was there. Upon arrival his temperature was 99.5°F, Pulse

- Myocarditis and Bradyarrhythmias are the common cardiological manifestations of Dengue
- Treatment is supportive
- IV fluid administration should be judicious

rate was 42/min with irregular volume, BP was 86/60 mm of Hg, RR was 24/min, Body weight was 23 Kg, multiple maculopapular rash appeared over right forearm on day⁵ of fever which was mildly pruritic. There was no petechiae over skin or in the oral cavity, no tonsillar patch or tonsillar enlargement, no lymphadenopathy, B/L vesicular breath sound without any adventitious sound heard over chest, per abdominal examination was appeared to be normal. Hemoglobin was 13.8 gm/dl, TLC- 5400/dl with polymorphonuclear cells 64% Lymphocytes was 31%, Hematocrit was 38.95, Platelet count was 1.2 lakhs/ml. Urea 19mg/dl, creatinine 0.5 mg/dl, Cardiac Troponin T was WNL, His LFT came to be Normal. Chest xray found to have no abnormality. MP and MPDA were negative. Ns1 Ag was positive on day 5 of fever and IgM Dengue Ab was strongly positive on day 6 of fever by Capture ELISA Method. ECG showed Complete AV dissociation with T wave inversion in leads V1 to V5 (Fig 1). This ECG features persisted for 2 days then changed to 2:1 AV Block but again became CHB after 3 days and finally persistent 2:1 AV block remained with the heart rate of around 44 to 48/m and narrow QRS complex. The T inversion remained same as of his first ECG at the time of admission. Echo revealed mild mitral regurgitation without chamber enlargement and normal biventricular systolic function (LVEF-68%) and without other valvular involvement and pericardial effusion. So provisionally he was diagnosed as Dengue fever complicated with AV nodal Disease. We started Intravenous fluid with 0.9% normal saline at a rate of 4ml/kg/hour for hypotension, oral paracetamol on sos basis, Inj atropine 0.5 mg Iv immediately followed by sos basis, injection

Department of Cardiology, ICVS, R G Kar Medical College and Hospital, Kolkata 700004

¹MD (Gen Med), DM (Cardiology), FESC, Professor and Head and Corresponding author

²MD (Gen Med), DM (Cardiology), Assistant Professor

³MD (Gen Med), Professor of General Medicine, RG Kar Medical College and Hospital, Kolkata 700004

⁴MD (Gen Med), DM Postdoctoral Trainee

⁵MD (Paediatric Medicine), DM Postdoctoral Trainee

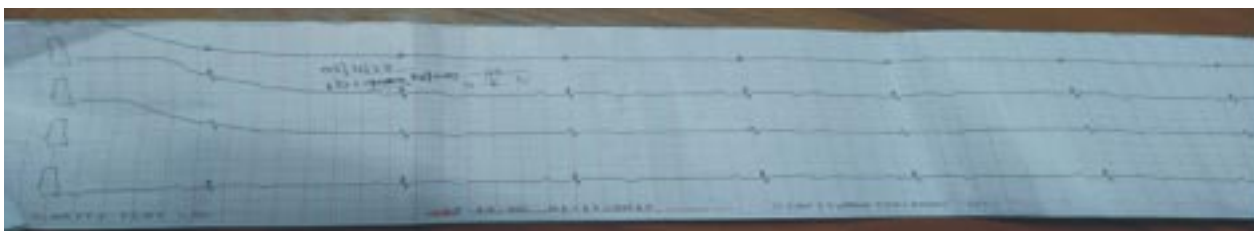

Fig 1 — Showing complete AV Dissociation

ceftriaxone 500 mg twice a day IV was continued for 5 days (2 days after the patient became afebrile), during the whole admission period he was under close observation in ICCU. After 2 days his BP became 110/70 mm of Hg, so we stopped fluid therapy but his pulse rate remained around 48-50/min. Temporary pacing was not done as there was no symptoms related to bradyarrhythmia. We performed regularly platelet count & TLC which were never came down and Hematocrit which was never gone up. He was kept under observation for 12 days after he became afebrile but no warning features developed except his pulse rate was around 48-50/min. Two weeks after discharge on follow up his BP was 110/70 mm of Hg and Pulse was irregular with average rate 68/min although ECG showed intermittent 2:1 AV block. Still we are following the patient at our OPD at regular basis.

Case 2 :

21 years female admitted with fever for 4 days with left sided precordial chest pain which is independent of chest movements and posture. Fever was not associated with any cough, expectoration, dysuria, pain abdomen, rash, arthralgia or myalgia, headache, hemoptysis or any other form of bleeding manifestations. On admission her temperature was 100.4°F , Pulse rate- 100/min, BP- 100/70 mm of Hg, RR-20/min. No dry or wet purpura noted, chest / abdomen appeared to be normal, Cardiovascular Examination revealed pericardial rub. Routine blood- revealed Leucopenia (TLC- 1740/ml with neutrophil 50%, Lymphocyte 40%) and Thrombocytopenia (Platelet -60,000/ml.) Electrolytes (Na⁺, K⁺), Urea, creati-

nine and LFT were normal. Cardiac Troponin T was positive (elevated). Dengue IgM Ab came to be positive on day 6 of fever. Chest X-ray showed- mild cardiomegaly with normal lung parenchyma. ECG on the day of admission was Normal (sinus tachycardia). Echo revealed- Dilated LV cavity (LVIDd-57mm,LVIDs-43mm), moderate Tricuspid regurgitation, mild Mitral regurgitation, depressed LV systolic function (LVEF = 35%) with chink of pericardial effusion. So provisionally she was diagnosed as Dengue fever with pancarditis with left ventricular systolic dysfunction. Day 2 of her admission she suddenly developed palpitation When her pulse rate was 150/m & BP was 96/60 mm of Hg, ECG done which revealed Non-sustained ventricular tachycardia (Fig 2), that was terminated by bolus injection of Amiodarone 150 mg IV followed by infusion over 24 hours. After 2-3 days she became afebrile, chest pain subsided after 5-7 days and no further episode of palpitation. Her Platelet count and TLC became normal. But echocardiographically her LV systolic function was as before (EF= 35-40%) but chamber size and mitral & tricuspid regurgitation were reduced to some extent (Figs 3-5). Now she is stable on Diuretics including spironolactone, beta blocker and ACE inhibitors. So finally she was diagnosed as Dengue fever with Left ventricular systolic dysfunction complicated with Ventricular Arrhythmias.

Review of Literature :

We searched PubMed database for articles published since 1975. Medical subject headings(MeSH) including dengue, myocarditis,

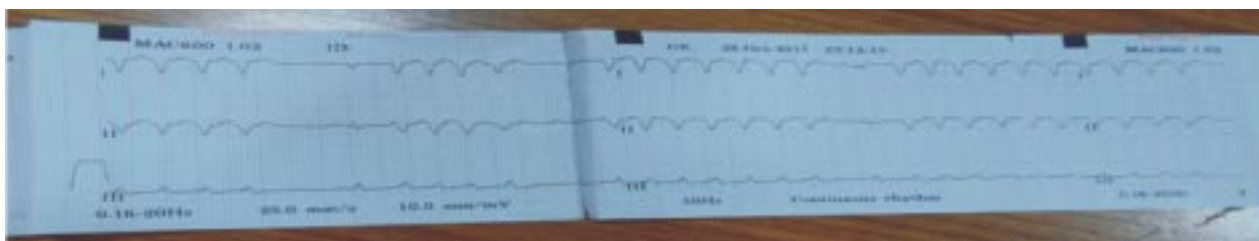

Fig 2 — Showing Non-sustained Ventricular Tachycardia

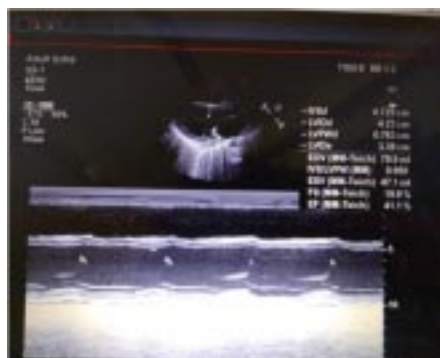

Fig 3 — Showing Dilated LV

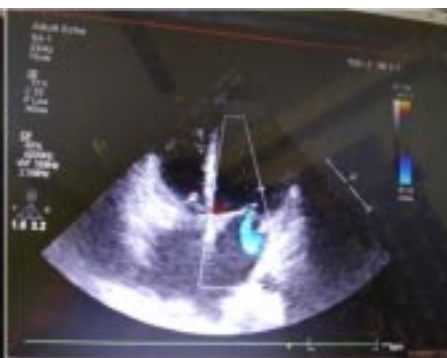

Fig 4 — Showing Mitral Regurgitation

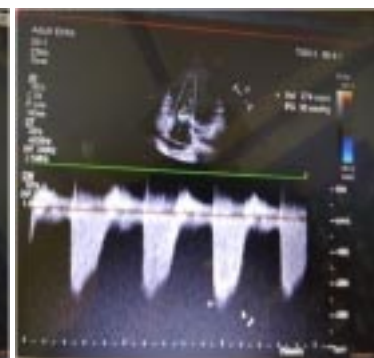


Fig 5 — Showing TR

pericarditis and arrhythmias were cross-referenced in the search which was supplemented with a secondary manual search.

Differing clinical severities were found, resulting from a wide spectrum of cardiac manifestations, which included self-limiting tachy-brady arrhythmia⁹⁻¹⁹ and myocardial damage with decreased left ventricular ejection fraction, leading to hypotension and pulmonary edema^{3,4,7,8,11,15,17}. Most of the affected patients were supportively treated for symptomatic relief^{3,4,6,7,11,15,17,19}; some patients with left ventricle failure required parenteral inotropic agents (ie, dopamine and/or ordobutamine) or vasopressor agents (Noradrenaline) for their cardiogenic shock. Although rare, fatal outcome was reported in dengue-affected patients with cardiac complications.

DISCUSSION

The incidence and clinical manifestations of cardiac complications in Dengue illness varies considerably^{2,8,9-19} from one series to another series. At one end of the clinical spectrum, patients are asymptomatic or have mild cardiac symptoms despite relative bradycardia, transient atrioventricular block or AV block which may persist upto 3 to 4 weeks and/or ventricular arrhythmia^{3,4,7,8,11,15,17,19}. At the other severe end, patients may experience acute pulmonary edema and/or cardiogenic shock due to severe myocardial cell damage with left ventricular failure. Myocarditis can masquerade as acute myocardial infarction. The exact mechanism of the cardiac injury in dengue fever remains unknown, however it is proposed that the direct invasion of the cardiac myocyte by the virus and damage to the cardiac cells by the ongoing inflammatory damage are the major mechanism^{20,21} of the cardiac manifestations. Dengue virus upon its entry in the body is taken up by the macrophages which causes activation of the T cells. These activated T cells cause release of various inflammatory cytokines, interleukins (IL1, IL2, IL6 etc), tumor necrosis factors (and activation of the complement pathway (C3a, C5a) and histamine⁵. This leads to the inflammation and necrosis of the endothelial cells leading to their dysfunction and plasma leakage. Leakage of the plasma in the interstitial space cause myocardial interstitial edema leading to impairment of myocardial function.

In our first case, the peculiar features was - the common conventional biochemical abnormalities ie, Thrombocytopenia, Leucopenia or raised hematocrit were absent, only cardiac involvement in the form of advanced AV nodal Block (2:1) and CHB were present. On the otherhand in our second case, in absence of Dengue hemorrhagic fever and Dengue shock syndrome (although there was thrombocytopenia and Leucopenia) there was Myocarditis in the form of Moderate to severe depressed LV systolic function with Malignant Ventricular arrhythmias (VT). So there was no correlation between the warning signs of Dengue fever (conventional features) and the cardiac manifestations in our two cases.

A recent report from Sri Lanka showed that 62.5% of 120 adults with dengue fever had an abnormal electrocardiogram³. These series suggest that cardiac complications in patients with dengue illness are not uncommon, and might have been under-diagnosed because most of the cases with cardiac complications are clinically mild and self-limited². Our review shows that cardiac complications are not uncommon in dengue illness. Although it was self-limiting in our patient under supportive treatment, acute myocarditis in dengue may be clinically severe to such an extent that it has a fatal outcome^{15,19}. Early recognition of myocardial involvement in dengue illness, prompt restoration of hemodynamic instability while avoiding fluid overload, and sparing unnecessary invasive man-

agement are important in treating dengue-affected patients with severe myocarditis.

Conclusion :

Cardiac manifestations of Dengue fever is not uncommon. Bradyarrhythmia and Heart failure due to Myocarditis are usual cardiac complications of Dengue, others being Ventricular tachycardia, Atrial fibrillation and valvular regurgitations. Low heart rate and hypotension may be due to cardiac involvement which should be evaluated by proper investigation like Electrocardiography and Echocardiography. Intravenous fluid administration to combat hypovolemic shock in Dengue should be monitored in presence of heart failure. Incidentally majority of bradyarrhythmias and heart failure as well as other cardiac manifestations resolve over time and don't require any active management.

REFERENCES

- Gibbons RV, Vaughn DW — Dengue: an escalating problem. *BMJ* 2002; **324**: 1563-6.
- Ravindral S, Kanagasinh A, Neomali A, Amerasena, Uditha B, DeshuVS — Asymptomatic myocardial involvement in acute dengue virus infection in cohort of adult Sri Lankans admitted to a tertiary referral centre. *Br J Cardiol* 2007; **14**: 171-3.
- Kularatne SA, Pathirage MM, Kumarasiri PV, Gunasena S, Mahindawanse SI — Cardiac complications of a dengue fever outbreak in Sri Lanka, 2005. *Trans R Soc Trop Med Hyg* 2007; **101**: 804-8.
- Wali JP, Biswas A, Chandra S, Malhotra A, Aggarwal P, Handa R, et al — Cardiac involvement in dengue haemorrhagic fever. *Int J Cardiol* 1998; **64**: 31-6.
- Khongphatthallayothin A, Chotivitayatarakorn P, Somchit S, Mitprasart A, Sakolsattayadorn S, Thisyakorn C — Morbitz type I second degree AV block during recovery from dengue hemorrhagic fever. *Southeast Asian J Trop Med Public Health* 2000; **31**: 642-5.
- Horta Veloso H, Ferreira Junior JA, Braga de Paiva JM, Faria Honorio J, Junqueira Bellei NC, Vicenzo de Paola AA — Acute atrial fibrillation during dengue hemorrhagic fever. *Braz J Infect Dis* 2003; **418**-22.
- Kabra SK, Juneja R, Madhuliika, Jain Y, Singhal T, Dar L, et al — Myocardial dysfunction in children with dengue haemorrhagic fever. *Natl Med J India* 1998; **11**: 59-61.
- Promphan W, Sopontammarak S, Pruekprasert P, Kajornwattanukul W, Kongpattanayothin A — Dengue myocarditis. *Southeast Asian J Trop Med Public Health* 2004; **35**: 611-3.
- Chuah SK — Transient ventricular arrhythmia as a cardiac manifestation in dengue haemorrhagic fever—a case report. *Singapore Med J* 1987; **28**: 569-72.
- Agarwal R, Kapoor S, Nagar R, Misra A, Tandon R, Mathur A, et al — A clinical study of the patients with dengue hemorrhagic fever during the epidemic of 1996 at Lucknow, India. *Southeast Asian J Trop Med Public Health* 1999; **30**: 735-40.
- Khongphatthanayothin A, Suesawalak M, Muangmingsook S, Bhattarakosol P, Pancharoen C — Hemodynamic profiles of patients with dengue hemorrhagic fever during toxic stage: an echocardiographic study. *Intensive Care Med* 2003; **29**: 570-4.
- Wiwanitkit V — Dengue myocarditis, rare but not fatal manifestation. *Int J Cardiol* 2005; **112**: 122.
- Neo HY, Wong RC, Seto KY, Yip JW, Yang H, Ling LH — Noncompaction cardiomyopathy presenting with congestive heart failure during intercurrent dengue viral illness: importance of phenotypic recognition. *Int J Cardiol* 2006; **107**: 123-5.
- Kularatne SA, Pathirage MM, Medagama UA, Gunasena S,

- Gunasekara MB — Myocarditis in three patients with dengue virus type DEN 3 infection. *Ceylon Med J* 2006; **51**: 75-6.
- 15 Malavige GN, Velathanthiri VG, Wijewickrama ES, Fernando S, JayaratneSD, Aaskov J, Seneviratne SL — Patterns of disease among adults hospitalized with dengue infections. *QJM* 2006; **99**: 299-305.
- 16 Lateef A, Fisher DA, Tambyah PA — Dengue and relative bradycardia. *Emerg Infect Dis* 2007; **13**: 650-1.
- 17 Khongphatthanayothin A, Lertsapcharoen P, Supachokchaiwattana P, La-Orkhun V, Khumtonvong A, Boonlarpaveechoke C, Pancharoen C — Myocardial depression in dengue hemorrhagic fever: prevalence and clinical description. *Pediatr Crit Care Med* 2007; **8**: 524-9.
- 18 Pesaro AE, D'Amico E, Aranha LF — Dengue: cardiac manifestations and implications in antithrombotic treatment. *Arq Bras Cardiol* 2007; **89**: e12-5.
- 19 Lee CH, Teo C, Low AF — Fulminant dengue myocarditis masquerading as acute myocardial infarction. *Int J Cardiol* 2009; **136**: e69-71.
- 20 Hober D, Poli L, Roblin B, Gestas P, Chungue E, Granic G, et al — Serum levels of tumor necrosis factor-alpha (TNF-alpha), interleukin-6 (IL-6), and interleukin-1 beta (IL-1 beta) in dengue-infected patients. *Am J Trop Med Hyg* 1993; **48**: 324-31.
- 21 Hober D, Delannoy AS, Benyoucef S, De Groote D, Wattre P — High levels of sTNFR p75 and TNF alpha in dengue-infected patients. *Microbiol Immunol* 1996; **40**: 569-73.

www.healthworldhospitals.com

DURGAPUR'S GIFT TO HEALTH CARE
TRANSPARENCY | HUMANITY | BELIEVABILITY



HEALTHWORLD HOSPITALS
MAKING A WORLD OF DIFFERENCE

Healthworld Hospitals, the latest & finest Tertiary Care Hospital of Eastern India has started its Journey in Durgapur Gandhi More...

- ⊕ Experienced & Super Specialist Doctors
- ⊕ Specially trained Medical Team
- ⊕ Latest Generation Infrastructure in healthcare in West Bengal & Eastern India
- ⊕ Ultra-Modern Laminar Flow Operation Theatre
- ⊕ 512 Slice CT Scan machine – First in India
- ⊕ Post Modern Cathlab
- ⊕ First Silent MRI In Eastern India
- ⊕ Package Facility in treatment without any hidden cost
- ⊕ Complete transparency in fully computerised billing system and apps
- ⊕ Healthcare with homecare



81700 55555/66660/66662

📍 Healthworld Hospitals, C-49 Commercial Area, Gandhi More, City Centre, Durgapur-713216, West Bengal, E-mail : info@healthworldhospitals.com

QUALITY HEALTHCARE @ HEALTHWORLD HOSPITALS
MAKING A WORLD OF DIFFERENCE

Our Super-specialities

Cardiology | Cardio-Thoracic & Vascular Surgery
Gastroenterology | Gastro-Intestinal (GI) Surgery
Neurology & Neuro-Surgery | Nephrology & Urology
Plastic & Reconstructive Surgery | Pulmonology & Chest Medicine



81700 55555/66660/66662

📍 C-49 Commercial Area, Gandhi More, City Centre, Durgapur 713216, West Bengal
E-mail : info@healthworldhospitals.com

www.healthworldhospitals.com