

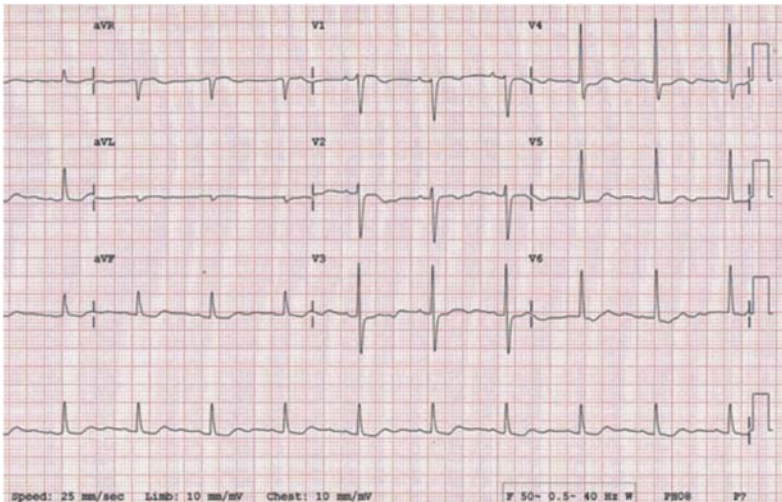
Pictorial CME

J INDIAN MED ASSOC

VOL 116, NO 2, FEBRUARY, 2018

ECG Quiz

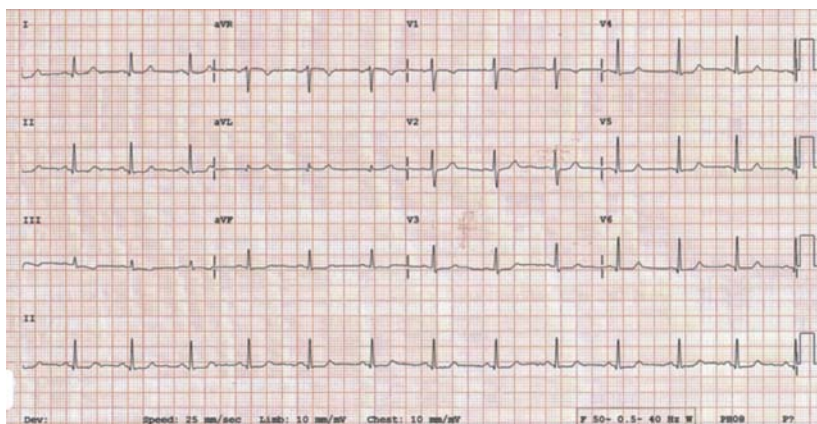
Meenakshi Chenniappan¹



ECG 1

Physician starts antiplatelet, statins

- 1. he is a fool
- 2. he is a genius
- 3. no comments



ECG 2

Which is abnormal here?

- (1) QRS
- (2) ST
- (3) T
- (4) ALL
- (5) NONE

¹MD, DM, FACC, FRCP, FACP, FCSI, FIAE, Emeritus Professor, The Tamilnadu Dr MGR Medical University & Senior Consultant Cardiologist, Ramakrishna Medical Centre and Apollo Speciality Hospitals, Trichy

(Answer page no 53)

We request you to send Quality Article addressed to :
Hony. Editor, Journal of IMA (JIMA),
53, Sir Nilratan Sircar Sarani (Creek Row), Kolkata 700014

Dr. Samarendra Kumar Basu
Hony. Editor, JIMA

Dr. Kakali Sen
Hony. Secretary, JIMA