

## Case Report

# Paraplegia following Subarachnoid Block

R Varaprasad<sup>1</sup>, K Priyathama Sankar<sup>2</sup>

Paraplegia, a serious complication following spinal anaesthesia is associated with significant morbidity and even mortality. Incidence of neurological complications following neuraxial block is between 1/1000 and 1/1,000,000. Neurological disturbances following spinal anaesthesia are less frequent. Most of the observed ones have been transient or have left minimal neural deficits. Rarely extensive and permanent damage to the nervous system may occur. Many problems concerning the pathogenesis of the neural complications of spinal anaesthesia remain unresolved. We are reporting a rare case of paraplegia following spinal anaesthesia given for total abdominal hysterectomy in an ASA physical status II patient. The delay in recovery of sensory and motor loss below T<sub>10</sub> (paraplegia) may be attributed to the triggering of acute myelitis due to spinal anaesthesia.

[J Indian Med Assoc 2018; 116: 48-50]

**Key words :** Paraplegia, transverse myelitis, spinal anaesthesia, bupivacaine.

### CASE REPORT

A 36 year old female, weighing 68 kilograms, presented with uterine fibroid, polycystic ovarian disease and chronic cervicitis, was posted for total abdominal hysterectomy. She has history of diabetes mellitus for eleven years and hypothyroidism for nine years. She was taking regular medication for both the diseases. Her fasting and postprandial blood sugars and thyroid profile were normal. Her fasting blood sugar on the day of operation was 85mg/dl. Her haemogram, serum electrolytes, renal function tests, electrocardiogram, echocardiography, chest X ray were normal. Vital parameters were normal.

Under strict aseptic precautions, spinal anaesthesia was given with 25 gauge Quincke's needle and 0.5% heavy bupivacaine 3ml (15mg) was given at lumbar 3rd-4th interspace. Sensory loss was up to the level of T<sub>8</sub> with adequate relaxation. Sensory loss was judged by pinprick and motor loss by Bromage scale. Surgery which lasted for forty five minutes was uneventful. Intraoperative parameters were within normal limits. Postoperative vitals were stable with a MAP of 90+/-10. One litre of Ringer lactate was transfused during surgery. The sensory and motor loss continued after the completion of surgery and was considered an abnormal delay in recovery.

Sensory loss below umbilicus and motor loss of both lower limbs persisted even on the first postoperative day. Motor power of lower limbs was 0/5, tone: hypotonic, reflexes absent, plantar reflex absent.

Sensory level: Loss of sensation below T10 level

Bilateral dorsalispedis pulsations were present.

Bowel and bladder reflexes were lost.

Neurophysician was consulted. MRI revealed acute myelitis. No epidural haematoma was found. Conus medullaris was mildly bulky with rounded contour.

Treatment was started with injection methylprednisolone

1gm intravenous in 100ml normal saline slowly over 20 minutes for 3 days followed by prednisolone 60mg orally along with physiotherapy.

On second postoperative day patient complained of heaviness and numbness of both upper limbs which subsided on third postoperative day with the present treatment.

A possibility of post spinal acute myelitis was considered. The status of the patient remained static and showed no improvement for nearly one month. After one month of treatment patient was complaining of weakness, numbness of both upper limbs, more on the left half of the body with visual disturbances floaters; fundoscopy was normal.

MRI repeated after one month showed no significant changes in the brain.

MRI spine revealed swelling and thickening of spinal cord extending from C<sub>2</sub> to conus medullaris (whole cord involvement)

Taking into consideration, a relapse of illness and progression of the lesion, a possibility of demyelinating illness, neuromyelitis optica was considered, Aggressive treatment was restarted with high doses of injection methylprednisolone followed by tapering doses of oral prednisolone. After immunoglobulin test, IgG 30 g was given for three days.

MRI repeated after three months showed atrophy of brain.

Subsequently, after a total period of six months the patient expired.

### DISCUSSION

Paraplegia, a serious complication following spinal anaesthesia is associated with significant morbidity and even mortality. Complications following regional anaesthesia have been recognised since a long time. Bier reported hundred years ago<sup>1</sup>. Although rare, neurological complications due to spinal anaesthesia are more than those of epidural. The studies being retrospective, the possible causes attributed are infection, febrile, immuno-compromised, pre-existing neurological disorders and those on anticoagulants<sup>2</sup>. Variations in the oxidative stress and antioxidant levels lead to auto immune disease. Thyroid hormone level is associated with the oxidative and antioxidant sta-

Department of Anaesthesiology, Maharajah's Institute of Medical Sciences, Vizianagaram 535217

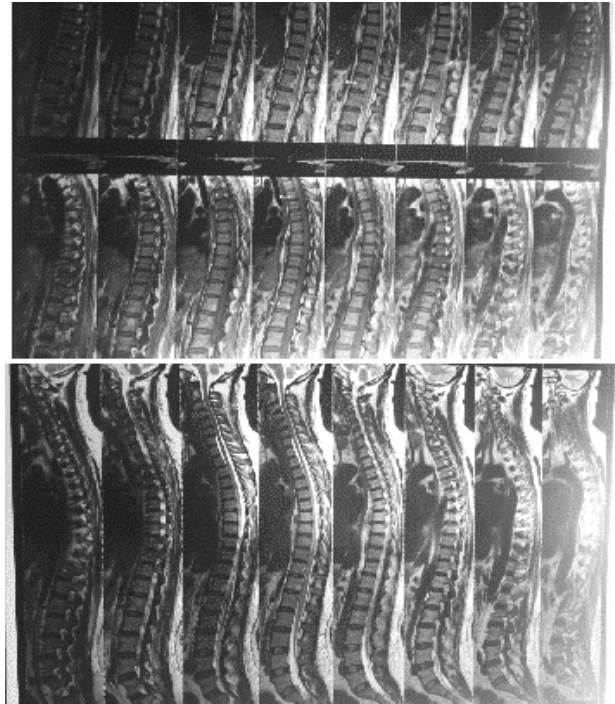
<sup>1</sup>MD, Professor

<sup>2</sup>MBBS, Postgraduate Student

tus. A study found that Acute Transversemyelitis patients had lower levels of TSH and FT3 and higher levels of FT4; the severity being inversely proportional to the levels of TSH and FT3<sup>3</sup>. Pathological studies have shown a relationship between diabetes mellitus and myelopathy, the posterior column lesion more common than the cortico-spinal tract. The combination of peripheral neuropathy, disturbed sense of position and/or vibration and pyramidal signs are suggestive of diabetic myelopathy. Although myelopathy is rare, it is one of the debilitating neurological complications of diabetes mellitus<sup>4</sup>. Pre-existing neurological injuries caused by abnormal medullary circulation like diabetes mellitus, atherosclerosis and cervical injury can lead to infarction of anterior 2/3 of the spinal cord causing flaccid paralysis of the lower limbs<sup>5</sup>. Paraplegia following spinal analgesia has been reported in case of congenital absence of lumbar vertebra<sup>6</sup>. Rare causes are GB syndrome, epidural abscess attributed to bacteraemia or neighbouring infectious process (1:50,000 patients) can coincide with the procedure<sup>7</sup>. Epidural haematoma can occur in obstetric patients with abnormal coagulation or low platelets, chronic renal failure hepatic cirrhosis and liver failure<sup>8</sup>.

Our prime concern was to exclude spinal anaesthesia as a cause for paraplegia- we needed to exclude spinal cord haematoma, spinal cord abscess, caudaequina syndrome, arachnoiditis, transverse myelitis, anterior spinal artery syndrome, disc prolapse, vertebral tuberculosis or vertebral metastasis. Urgent MRI of the brain and spinal cord was done to come to a diagnosis. The changes are mild abnormal altered T2W hyperintensities noted in dorsolumbar from D2 to L1 level with mild expansion of the cord and heterogeneous T2W and signal changes confirmed of acute transversemyelitis.

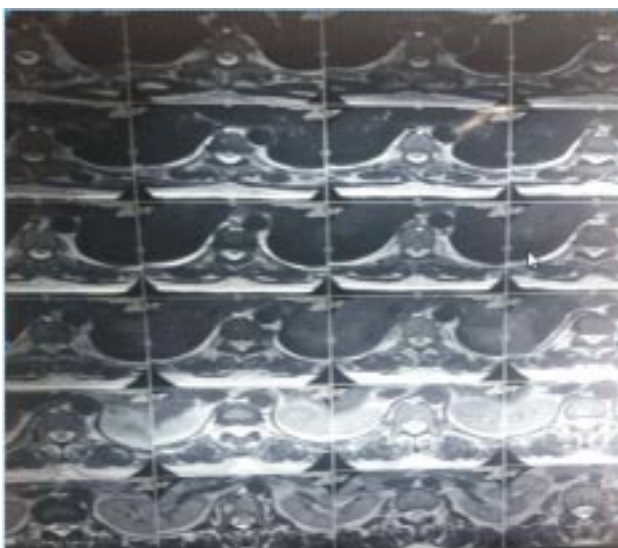Philip K Bromage has classified neurological complications into three classes- those from non-anaesthetic causes,, or underlying pathology aggravated by regional analgesia and those related to regional analgesia<sup>9</sup>. In a metanalysis of 65,206 patients, five had neurological sequelae - epidural block with 2% procaine, 1% lignocaine with or without 1:20000, 000 adrenaline, mepivacaineand chlorprocaine<sup>10</sup>. The deficits ranged from flac-




MRI of total spine

cid paralysis to cellular degeneration of the anterior two third of the spinal cord<sup>9</sup>. Delayed recovery from epidural labour analgesia occurred in two cases with 2% chlorprocaine. One patient recovered in 72 hours and the other made partial recovery in four weeks<sup>11,12</sup>. Complete flaccid paralysis was reported by Sameer et al in an eighteen year old patient without any underlying cause as all preoperative investigations were normal. So, a probable diagnosis of aseptic or viral meningitis was made<sup>13</sup>.

Our patient had no pre-existing neurological disorder; she was suffering from diabetes mellitus for eleven years and hypothyroidism for nine years but under control. Rest of the preoperative investigations were normal. Strict aseptic precautions were taken during spinal puncture and the same batch of local anaesthetic was used for many other patients. Immediate post-operative MRI was transverse myelitis which was triggered by spinal anaesthesia was the probable cause of the paraplegia, subsequently quadriplegia and respiratory muscle paralysis leading to her death.



MRI of dorsal spine



### CONCLUSION

Long standing hypothyroidism can lead to autoimmune disorder in the form of acute tranverse myelitis. The associated diabetes mellitus can be an aggravating factor to the disease. Any intervention such as neuroaxial blocks or nerve blocks can precipitate neurological complications. General anaesthesia would be a better option.

### REFERENCES

- 1 Aromaa U, Lahdensuu M, Cozanitis DA — Severe complications associated with epidural and spinal anaesthetics in Finland 1987-1993. A study based on patient insurance claims. *Acta Anaesthesiol Scand* 1997; **4**: 445-52.
- 2 Chiapparini L, Sghirlanzoni A, Pareyson D, Savoiardo M — Imaging and outcome in severe complications of lumbar epidural anaesthesia: report of 16 cases. *Neuroimaging* 2000; **42**: 564-71.
- 3 Weng Y, Lin H, Ye X *et al* — Neuroreport 28(5): 1Feb17 Ref Giladi N, Turezkite T, Harel D [www.ncbi.nlm.nih.gov/pubmed/2061017](http://www.ncbi.nlm.nih.gov/pubmed/2061017).
- 4 Giladi N, Turezkite T, Harel D — [www.ncbi.nlm.nih.gov/pubmed/2061017](http://www.ncbi.nlm.nih.gov/pubmed/2061017).
- 5 Dahlgren N, Tomebrandt K — Neurological complications after anaesthesia. A follow up of 18,000 spinal and epidural anaesthetics performed over three years. *Acta Anaesthesiol Scand* 1995; **39**: 872-80.
- 6 Horlocker TT, Heit JA — Low molecular weight heparin: biochemistry, pharmacology, perioperative prophylaxis regimens and guidelines for regional anesthetic management. *Anesrg Analg* 1997; **8**: 874-85
- 7 Bier A — Versuche ueber cocainisierung des rueckemarks. *Deutch Zeitchrijt fuer chirargie* 1899; **15**: 361-68.
- 8 Agrwal A, Kishore K — *Indian Journal of Anaesthesia* 2009; **53**: 543-53.
- 9 Wilinski JA, Bollini C — Complicaceoneurologes de origen no anaesthesero Editorial Medika Pan Americana Buenos Aires, *Argentina* 1999; **5**: 69-84
- 10 Shivani Rastogi, Rajlaxmi Bhandari, Virendra Sharma, Tarun PandeymInian — *Journal of Anaesthesia* 2014; **58**: 484-6.
- 11 Renck H Neurological comlications of central nerve blocks *ActaAnesthesiolScand* 1995; **39**:859-868
- 12 Naulty J, Becker RA. Bloqueo del neuro ejeparael partoporcesarea. En Analgesia y analgesia epidural y raquideatemas contemporaneous. Clinicas de Anestesia de Nortamerica. Nueva editorial Interamericana, Mexico DF 1992:122
- 13 Bromage PR — Neurological complication of subarachnoid and epidural anesthesia. *Acta Anesthesiol Scand* 1997, **41**: 439-44.
- 14 Robert E — Kane Neurological deficits following epidural or spinal anaesthesia *Anesth Analg* 1981; **61**: 150-60.